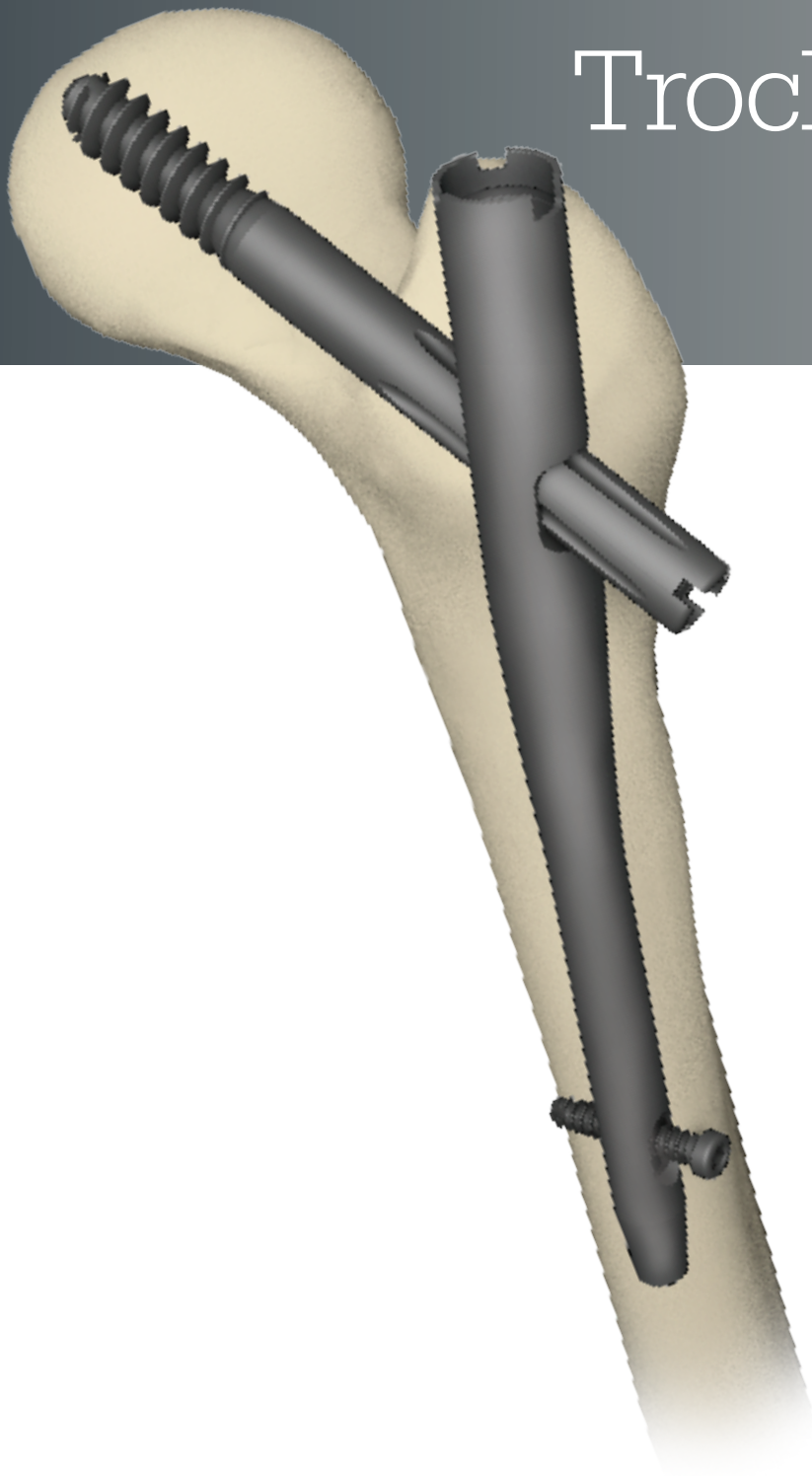


stryker

Gamma3[®]

Trochanteric Nail
170 & 180



Operative technique

Gamma3

Trochanteric Nail 170 & 180

Contents

1. Design of the Gamma3 System	4
Gamma Nail 170 and 180	4
Distal locking screws	5
2. Indications and contraindications	6
3. Operative technique	8
Pre-operative planning	9
Implant selection	9
Patient positioning	10
Incision	11
Entry point	13
Opening the cortex	13
Preparation of medullary canal	14
Assembly of targeting device	20
Nail insertion	23
Lag screw positioning using one shot device	25
Lag screw insertion	26
Pre-drilling the lateral cortex	27
Lag screw insertion	28
Lag screw fixation	31
Distal screw locking	35
End cap insertion	37
Nail extension end caps	38
Post-operative care and rehabilitation	38
Extraction of the Gamma3 implants	39
Dealing with special cases	41
Packaging	42

This publication sets forth detailed recommended procedures for using Stryker devices and instruments.

It offers guidance that you should heed, but, as with any such technical guide, each surgeon must consider the particular needs of each patient and make appropriate adjustments when and as required. A workshop training is recommended prior to first surgery.

All non-sterile devices must be cleaned and sterilized before use. Follow the instructions provided in our reprocessing guide (L24002000). Multi-component instruments must be disassembled for cleaning. Please refer to the corresponding assembly/disassembly instructions.

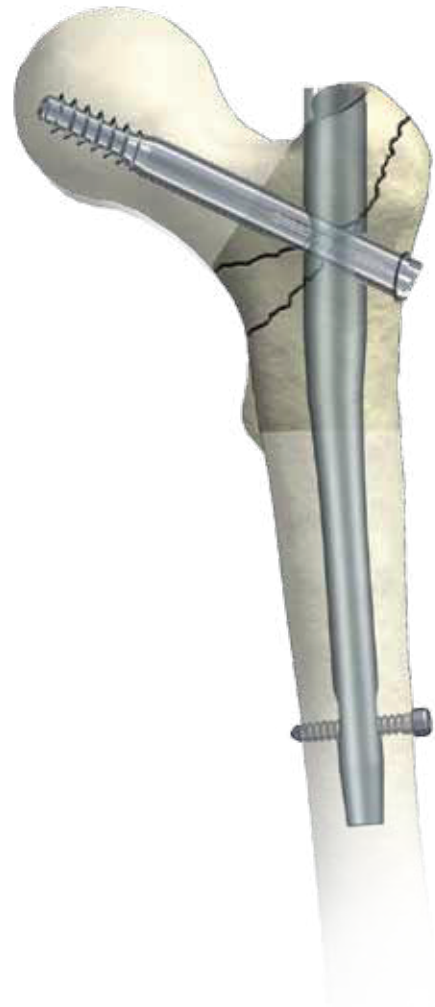See package insert (L22000007) for a complete list of potential adverse effects, contraindications, warnings and precautions. The surgeon must discuss all relevant risks, including the finite lifetime of the device, with the patient, when necessary.

Warning:

Fixation screws:

Stryker bone screws are not approved or intended for screw attachment or fixation to the posterior elements (pedicles) of the cervical, thoracic or lumbar spine.

Stryker systems have not been evaluated for safety and use in MR environment and have not been tested for heating or migration in the MR environment, unless specified otherwise in the product labeling or respective operative technique (Fig. 7).



Design

The Gamma3 System

Gamma3 Locking Nails come in 3 neck-shaft angles of 120, 125 and 130°.

All nails* use the same lag screws, set screw, distal locking screws and end caps (Fig. 1).

Gamma3 Nail 170 and 180

The anatomical shape of the nail is universal for all indications involving the treatment of trochanteric fractures. The nail is cannulated for guide-wire-controlled insertion.

A range of three different neck-shaft angles are available for lag screw entry to accommodate variations in femoral neck anatomy.

A single distal locking screw is provided to stabilize the nail in the medullary canal and to help to prevent rotation in complex fractures. The oblong hole allows static or dynamic locking.

Technical specifications:

- **Material:**
Titanium alloy with anodized type II surface treatment.
- **Nail length:**
170mm, 180mm
- **Nail diameter:**
180mm:
proximal 15.5mm, distal: 11mm
170mm:
proximal 15.5mm, distal: 10mm
- **Proximal nail angle range:**
120°, 125°, 130°
- **M-L bend for valgus curvature:**
4 degrees
- **End caps** in lengths of
0mm, +5mm and +10mm
- **Distal oblong hole** for
5mm screws; up to 5mm
dynamization is possible

Distal locking options

- Locking in the distal part of the oblong hole creates a dynamic locking mechanism (Fig. 2).
- Locking in the proximal part of the oblong hole allows static locking of the nail (Fig. 3).

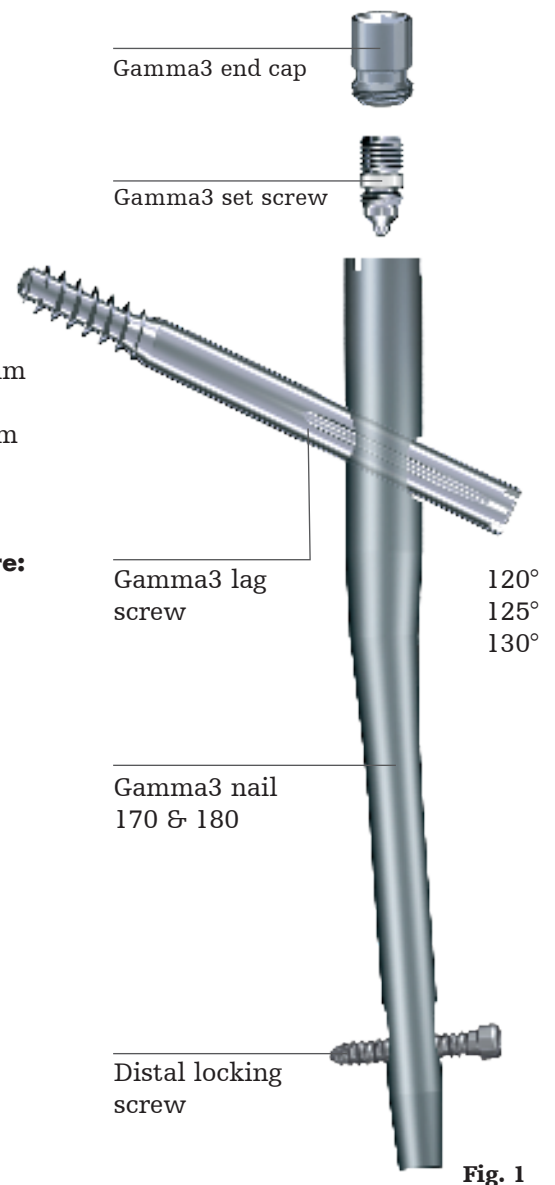


Fig. 1



Fig. 2



Fig. 3

* Each nail is supplied sterile packaged together with a set screw in one box.

Design

Lag screw and set screw function

Technical specifications

- Lag screw diameter: 10.5mm
- Lag screw lengths: 70–130mm in 5mm increments
- Lag screw design for high load absorption and easy insertion
- Asymmetrical depth profile to allow the lag screw to slide in the lateral direction only (see orange arrow on Fig. 4).
- Self retaining set screw to protect the lag screw against rotation and simultaneously allowing sliding of the lag screw laterally.

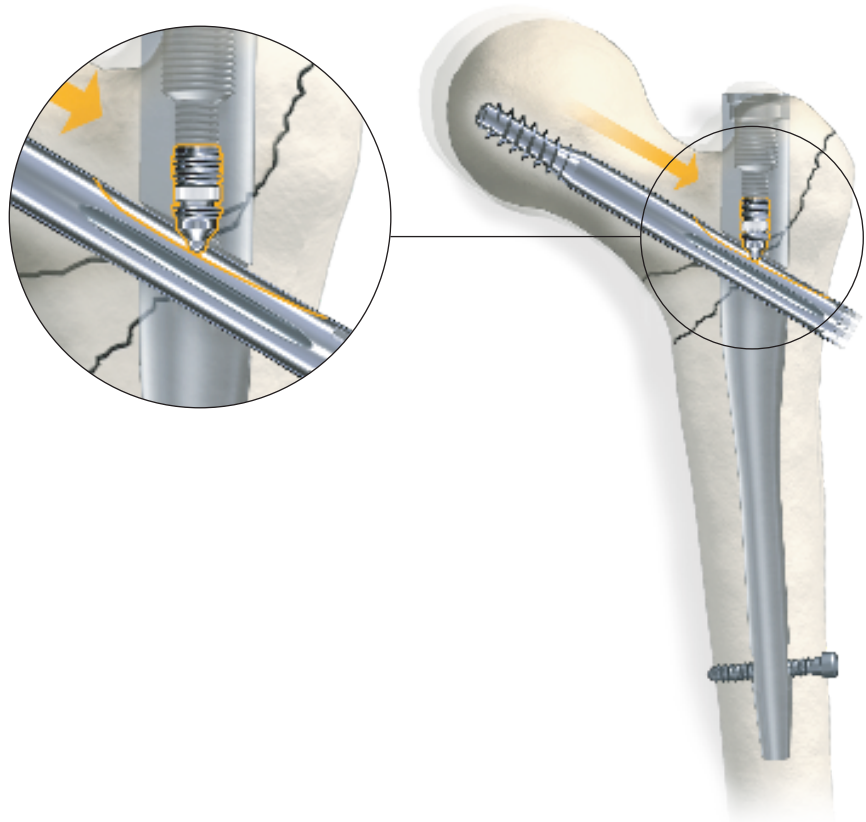


Fig. 4
Lag screw stabilization system

Distal locking screws

Length definition of the distal locking screw

The distal locking screw is measured from head to tip (Fig. 5).

Technical specifications

- Distal locking screw diameter: 5mm.
- Distal locking screw lengths ranging from 25–50mm, in 2.5 and 5mm increments. Longer screws up to 120mm are available on request.
- Fully threaded screw design. Partially threaded screws are available on request.

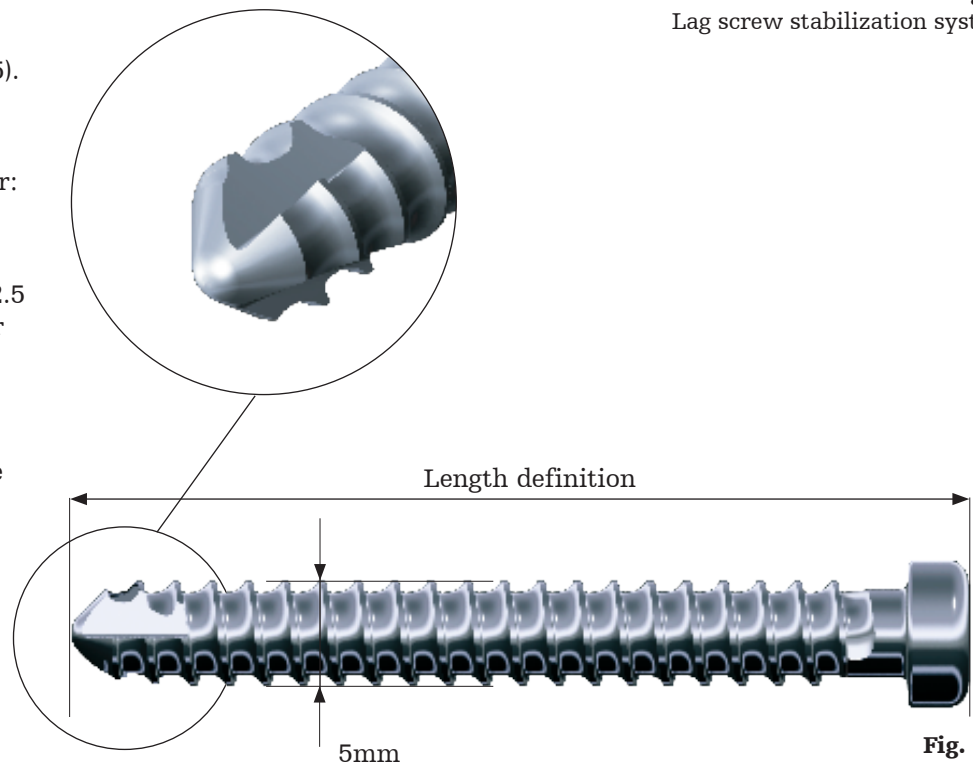


Fig. 5

Indications and contraindications

Intended use

The Trochanteric Gamma3 Nail is intended for use in stabilizing various types of stable and unstable intertrochanteric fractures including peritrochanteric fractures.

Indications

The Trochanteric Gamma3 Nail is indicated for fixation of stable and unstable intertrochanteric fractures, including but not limited to nonunion, malunion and tumor resections.

Contraindications

Contraindications are medial neck fractures and sub-trochanteric fractures.

Caution:

The Gamma3 Nail is designed for temporary implantation until the bone consolidation occurs. Therefore, if no bone consolidation occurs or if consolidation is not sufficient, the system may break. The aim of post-operative care must be to ensure the promotion of bone consolidation. The Gamma Nail is not intended for full weight bearing in patients with complex unstable fractures until sufficient bone consolidation is confirmed in the follow up X-rays.

This operative technique has been devised in consultation with leading surgeons in many countries to be a basic guide, particularly for less experienced users of the Gamma3 System. It is acknowledged that several alternative approaches to certain elements of the procedure are available, and may have advantages for particular situations or surgeons.

Caution:

The coupling of elastosil handles contains a mechanism with one or multiple ball bearings. In case of applied axial stress on the elastosil handle, those components are pressed into the surrounding cylinder resulting in a complete blockage of the device and possible bending.

To avoid intra-operative complications and secure long-term functionality, we mandate that elastosil handles be used only for their intended use. DO NOT HIT any elastosil handles.

Care should be taken to utilize the cleaning stylet for intra- and post-operative cleaning of cannulated instruments. Rinsing with saline solution can help prevent accumulation of debris.



Fig. 7

Operative
technique

Operative technique

Pre-operative planning

The Gamma3 Nail with a 125° nail angle may be used in the majority of patients.

Where such variations in femoral anatomy require an alternative, the following chapter describes how to select the optimum implant size.

Implant selection

X-ray templates are very helpful during pre-operative planning. Use the X-ray templates for short and long nails to select the correct implant and the optimal nail angle. These templates show the true implant size at a magnification of 15% in anterior-posterior view. The X-rays should be taken at this magnification (15%) for an optimum surgical outcome (Fig. 9). If accurate anatomical reduction has been achieved, the X-ray can be taken from the fractured hip or from the contralateral side. Alternatively the femoral neck angle, i. e. the angle between the femoral shaft mid-axis and the femoral neck mid-axis, could be measured using a goniometer.

In case the X-ray templates do not show an anatomical fit with the bone, a different implant solution should be considered.

Note:

Please ensure precise alignment of the affected hip joint when using these templates. Template magnification is 15%. All dimensions (nail angle and implant sizing) resulting from using these templates must be verified intra-operatively to ensure proper implant selection.

Stryker Imaging offers also the Advanced Case Plan including digital template for Gamma3 System as an alternative.

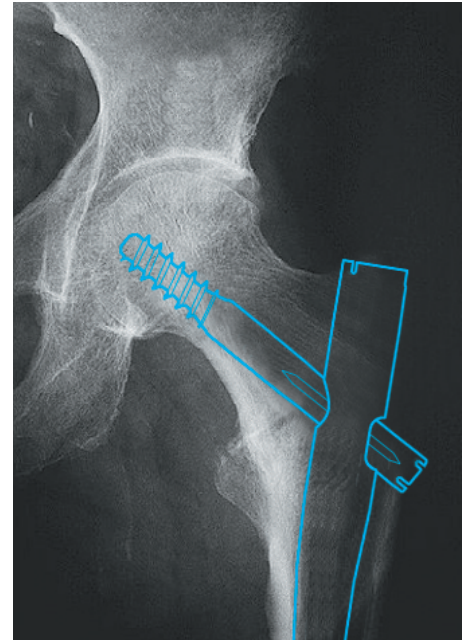


Fig. 9
X-ray in a-p view, showing implant

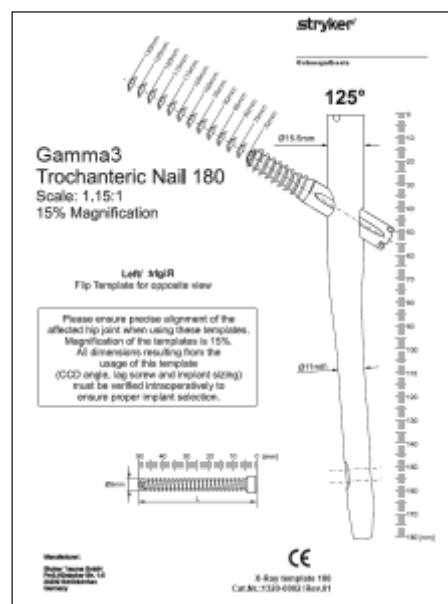


Fig. 9a
Gamma3 Nail 180 X-ray Template
(Ref. No 1320-0002)

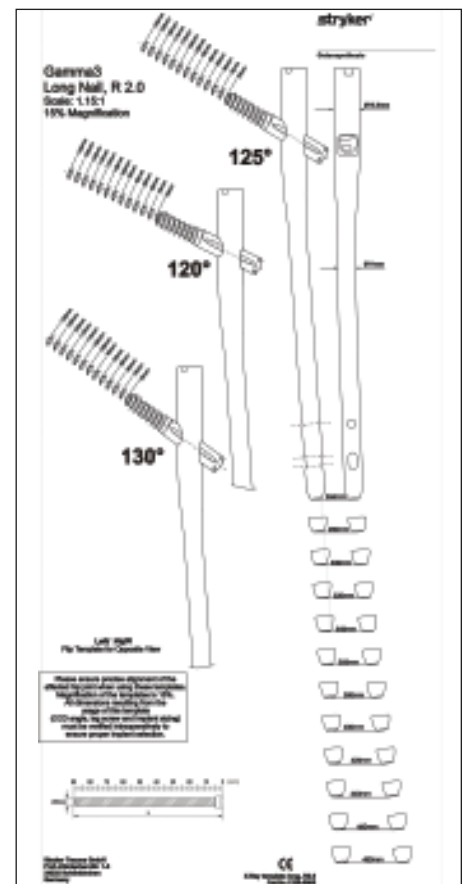


Fig. 9b
Gamma3 Long Nail X-ray Template
(Ref. No 1320-0005)

Operative technique

Patient positioning

The patient is placed in a supine position on the fracture table and closed reduction of the fracture is recommended. Reduction should be achieved as anatomically as possible. If this is not achievable in a closed procedure, open reduction may be necessary.

Traction is applied to the fracture, keeping the leg straight. The unaffected leg is abducted as far as possible to make room for the image intensifier (Fig. 10).

Maintaining traction, the leg is internally rotated 10–15 degrees to complete fracture reduction; the patella should have an either horizontally or slightly inward position (Fig. 11).

Position the image intensifier so that anterior-posterior and mediolateral views of the trochanteric region of the affected femur can be easily obtained. This position is best achieved if the axis of rotation of the intensifier is centered on the femoral neck of the affected femur (Fig. 12).

It is important to ensure that a view of both the distal and proximal ends of the nail can be obtained during the procedure without obstruction by the traction table.

The patient is then prepared and draped as for standard femoral nailing procedures. When positioning the drapes, bear in mind that the incision will be proximal.

Reduction should be achieved as anatomically as possible. If this is not achievable, reduction should be achieved at least in one plane. Reduction in the other plane may be achieved with the Gamma3 Nail during insertion.

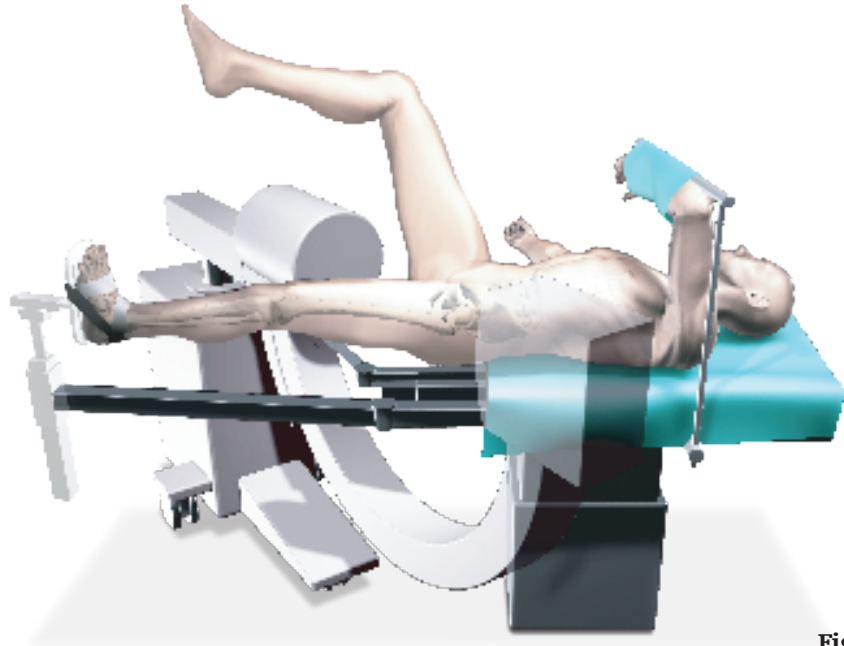


Fig. 10

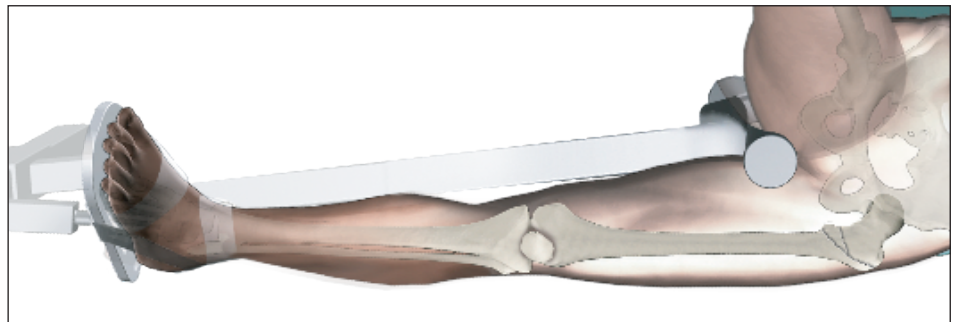


Fig. 11

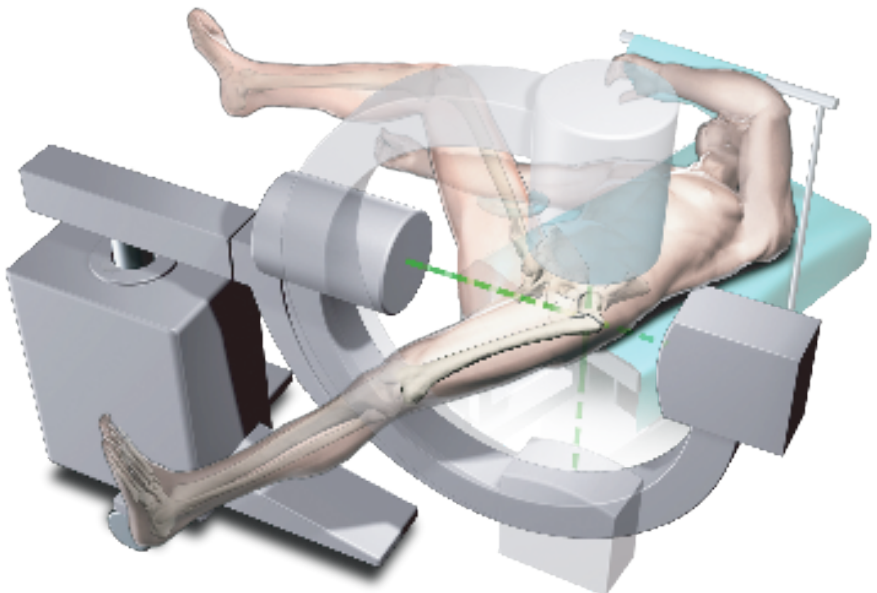


Fig. 12

Operative technique

Incision

Incisions may be developed in different manners. Two alternatives will be described below.

Alternative 1:

The tip of the greater trochanter may be located by palpation (Fig. 13) and a horizontal skin incision of approximately 2–3cm is made from the greater trochanter in the direction of the iliac crest (Fig. 14). In larger patients the incision length may need to be longer, depending on BMI of the patient.

A small incision is deepened through the fascia lata, splitting the gluteal muscle approximately 1–2cm immediately above the tip of the greater trochanter, thus exposing its tip. A self-retaining retractor, or tissue protection sleeve is put in place.

Alternative 2:

A long and thin metal rod (e.g. screw scale, long) is placed on the lateral side of the leg. Check with the image intensifier, using M-L view, that the metal rod is positioned parallel to the bone in the center of the proximal part of the femoral canal (Fig. 16a). A line is drawn on the skin (Fig. 16).

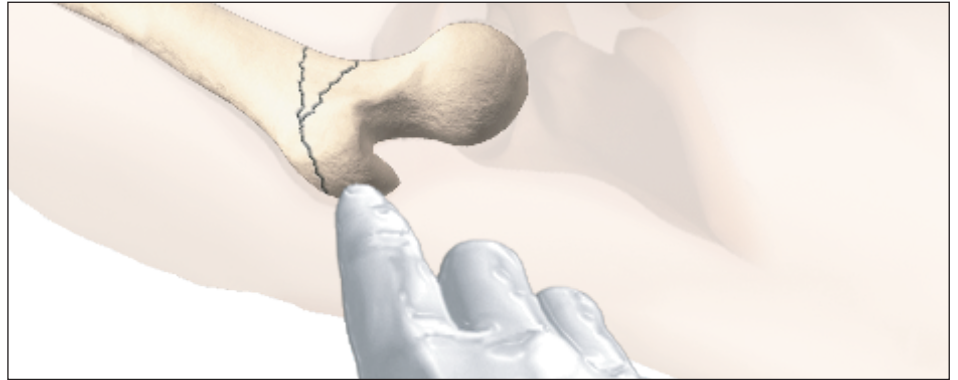

Fig. 13




Fig. 14

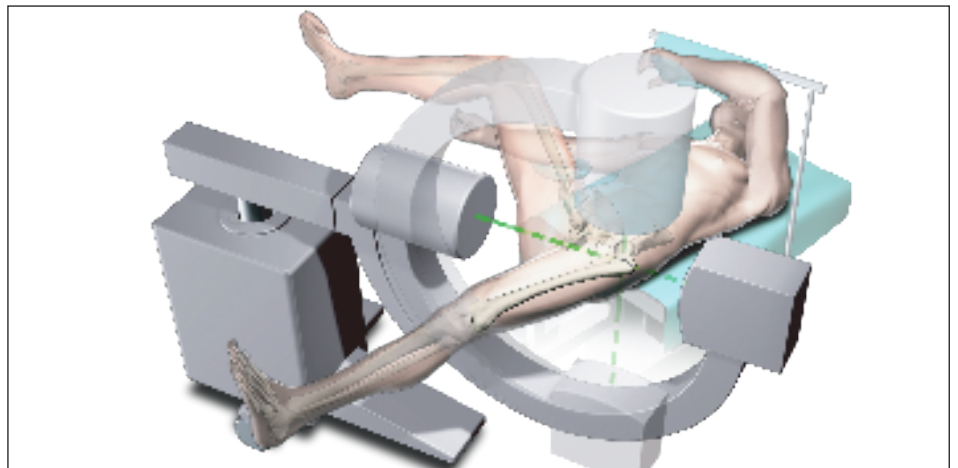


Fig. 15

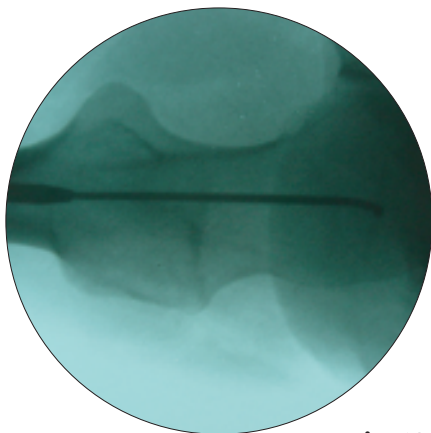


Fig. 16a



Fig. 16

Operative technique

The C-arm is turned approx 90° to provide an A/P image of the tip of the trochanter using the metal rod as shown in Figure 17 and 17a.

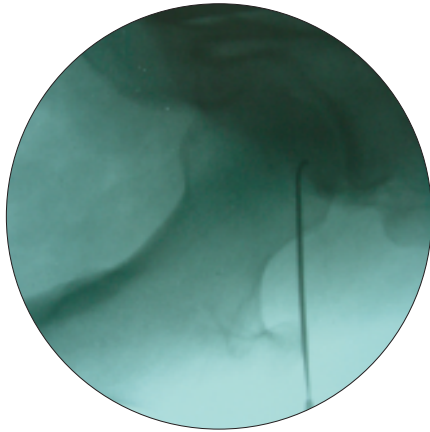


Fig. 17a

A vertical line is drawn onto the skin (Fig. 18). The intersection of the lines indicates the position for the entry point of the nail. This is usually the anterior third of the tip of the greater trochanter as shown in Fig. 19.

The skin incision is made cranially to the indicated intersection, following the sagittal line in cranial direction. The distance between the intersection and the starting point for the incision differs, depending on the obesity of the patient. Under normal conditions it is a distance of approximately 2cm's.

A small skin incision is made as described in alternative 1 and shown in Fig. 20.

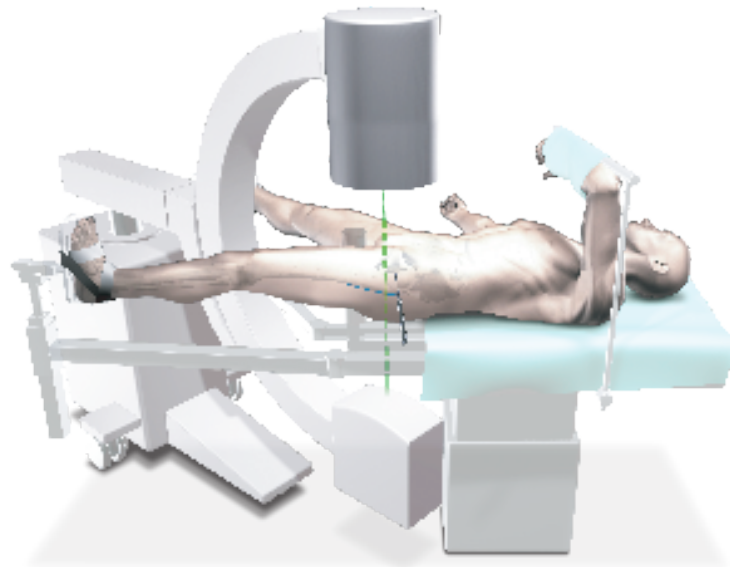


Fig. 17

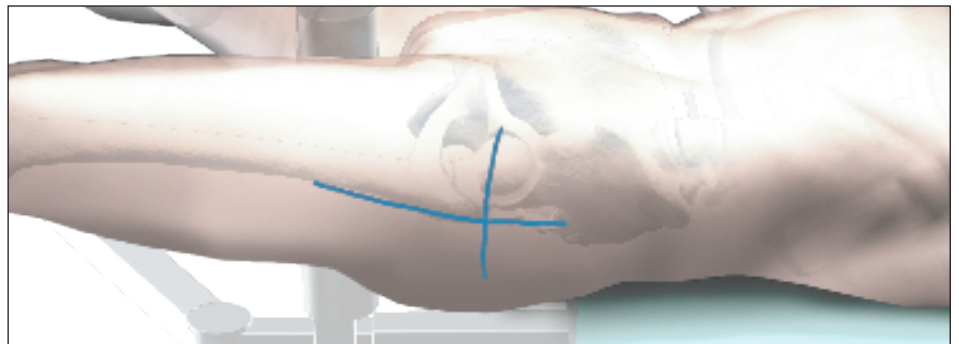

Fig. 18

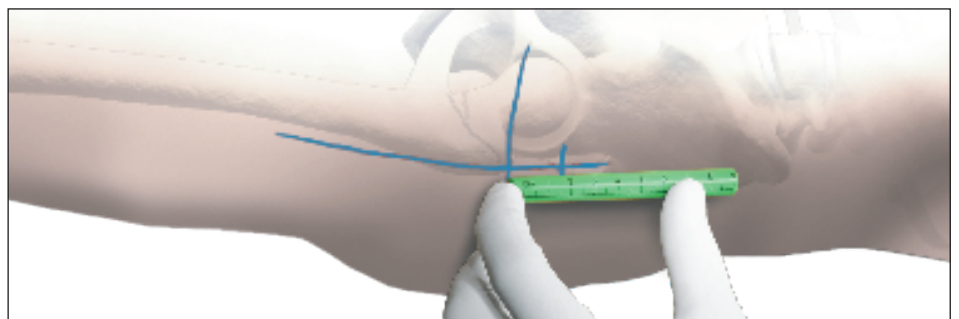


Fig. 19

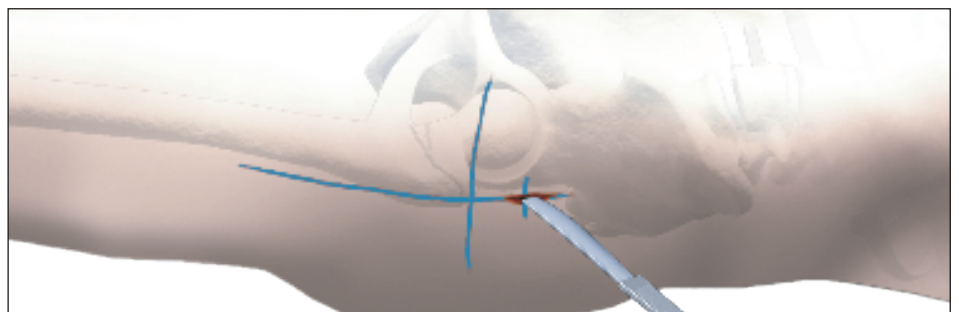


Fig. 20

Operative technique

Incision

Using a finger, the tip of the trochanter should be felt easily (Fig. 21).

Entry point

The correct entry point is located at the junction of the anterior third and posterior two-thirds of the tip of the greater trochanter and on the tip itself (Fig. 22).

Opening the cortex

The medullary canal has to be opened under image intensification. The use of the cannulated curved awl (Fig. 23) is recommended if conventional reaming or the One Step Conical Reamer will be used to prepare the canal for the nail.

Caution:

During opening the entry point with the awl, dense cortex may block the tip of the awl. An awl plug can be inserted through the awl to avoid penetration of bone debris into the cannulation of the awl shaft.

The optional rasp awl combines the feature of the rasp and awl to prepare the proximal femur for the Gamma3 Nail. It may provide an option to open the proximal femur cavity without further reaming (Fig.24).

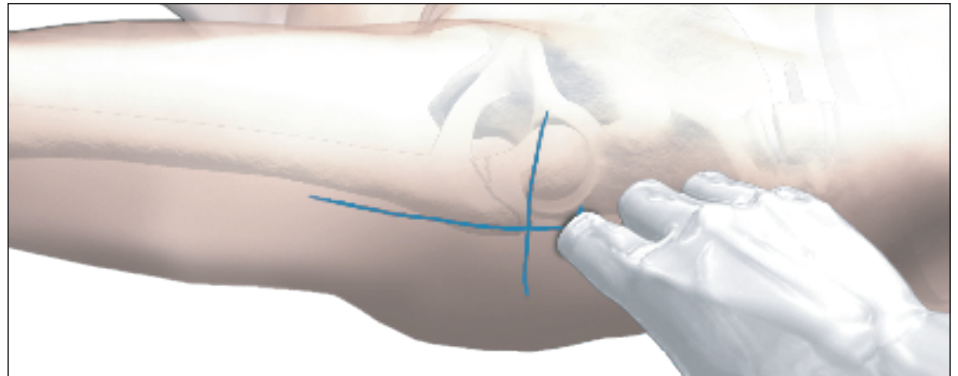


Fig. 21

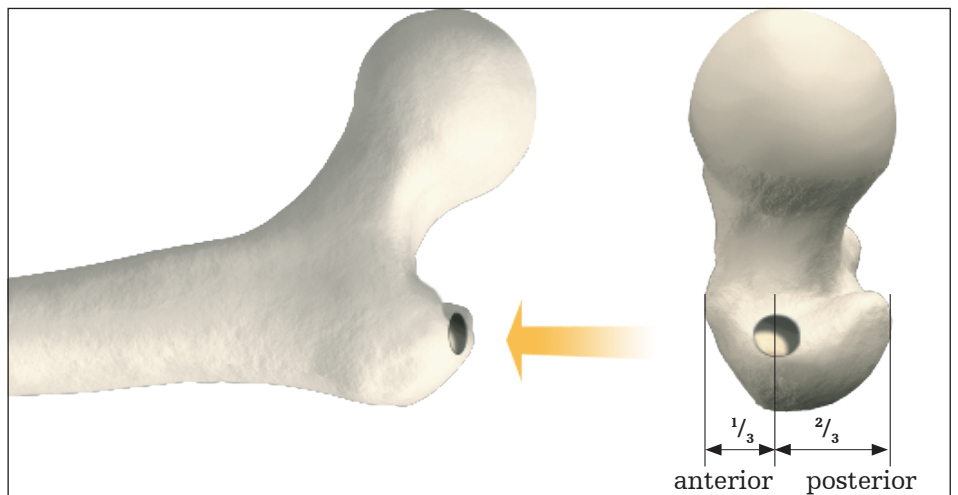


Fig. 22

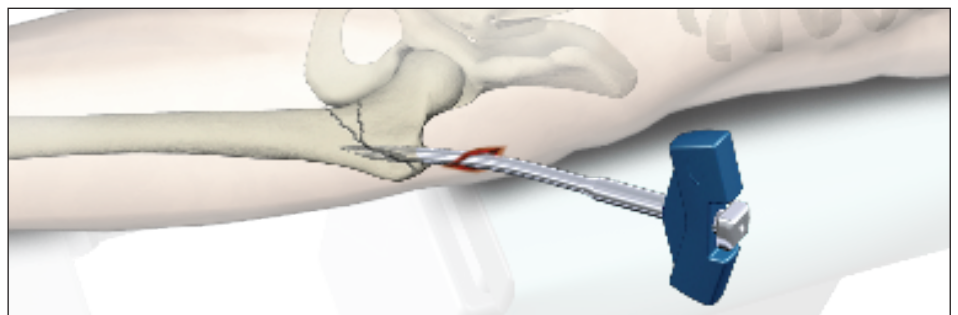


Fig. 23

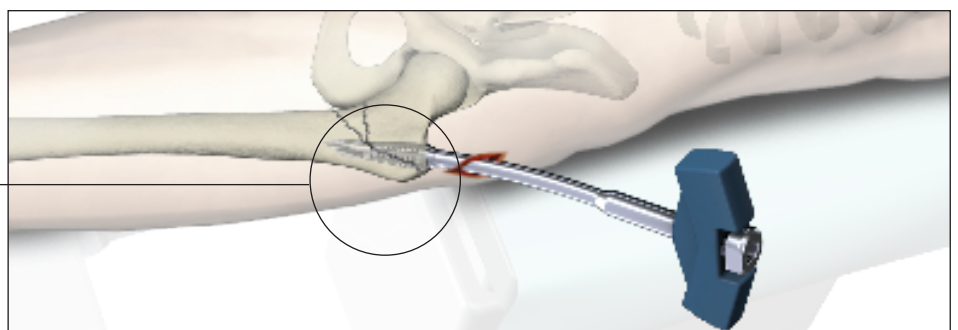
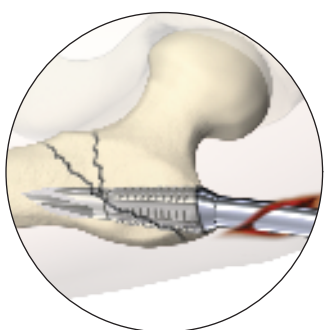


Fig. 24

Operative technique

Preparation of the medullary canal

The Gamma3 System includes four options to prepare the medullary canal. These options are described below.

Alternative 1: Reaming the medullary canal

A 3mm ball-tipped guide wire is recommended as a reamer guide. Pass the reamer guide wire through the cannulated curved awl into the shaft of the femur as shown, using the guide wire handle (Fig. 25).

Rotating the guide wire during insertion makes it easier to achieve the desired position in the middle of the medullary canal.

Flexible reamers are used to ream the shaft of the femur in stages starting from 9mm diameter and increasing in 0.5mm increments (Fig. 26).

The canal should be reamed at least 2mm larger than the distal diameter of the nail. In some narrow medullary canals, reaming may be necessary to achieve this (Fig. 27).

When reaming is performed, the entire femoral canal should be over-reamed down through the isthmus, in order to avoid stress riser in the bone.

In order to accommodate the proximal part of the Gamma3 Nail, the subtrochanteric region must be opened up to 15.5mm (Fig. 28). This can be done either by reaming with the Stryker Bixcut Reaming System (Fig. 26) or, alternatively, with the one step conical reamer. For soft tissue protection, the conical reamer sleeve should be used during reaming.

Caution:

Care must be taken with flexible reamers to ensure that the guide wire is not displaced laterally during reaming. This could lead to resection of more bone on the lateral side, which in turn would lead to an offset position for the nail and a risk of shaft fracture.

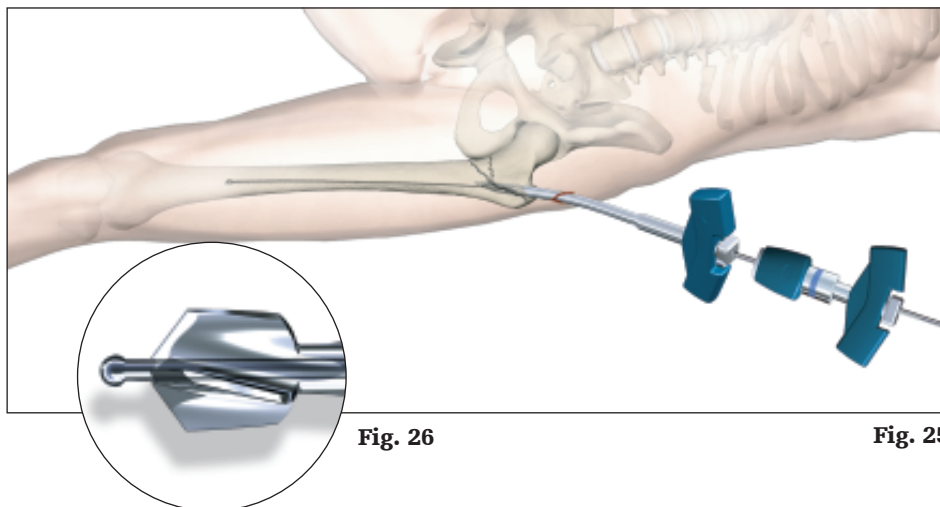


Fig. 26

Fig. 25

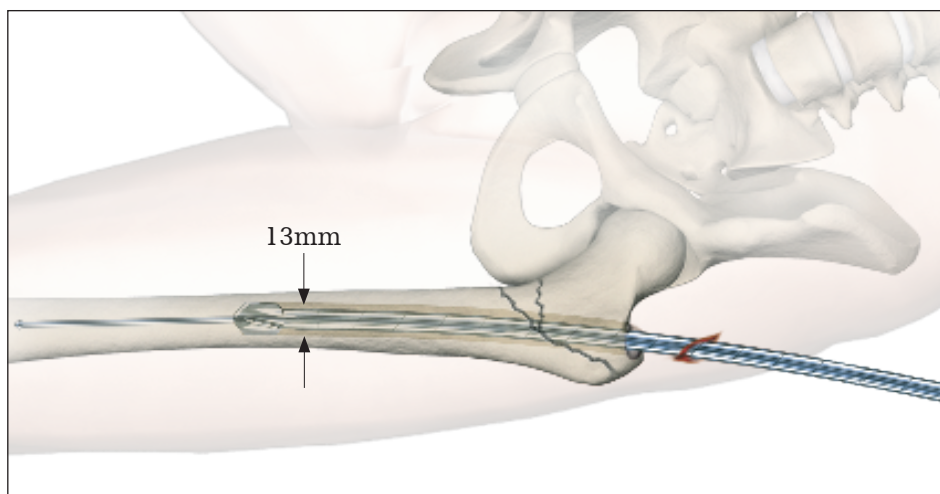


Fig. 27

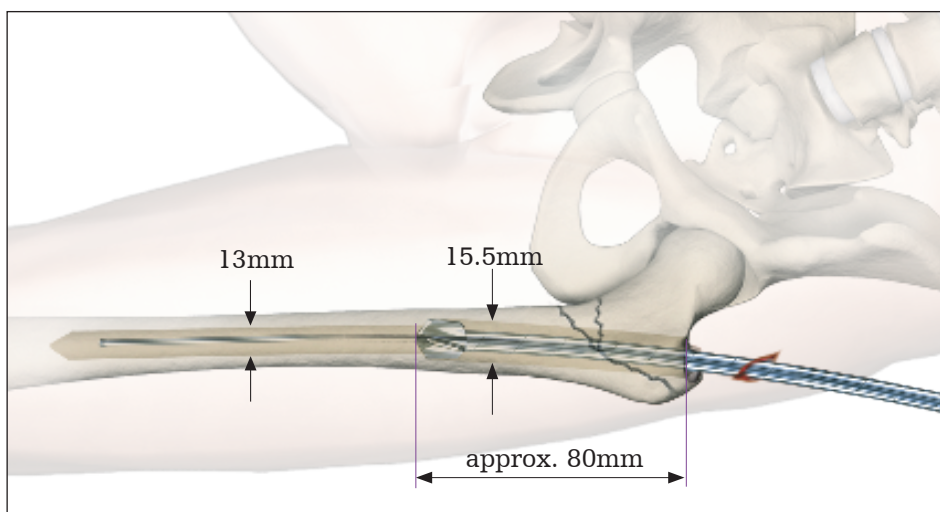


Fig. 28

Operative technique

Alternative 2: One step conical reamer

The one step conical reamer is an optional instrument and has been developed to provide surgeons with another option to prepare the proximal canal of the trochanter using only one drilling step. When the Gamma3 Nail 180 is used, reaming of the subtrochanteric and diaphyseal region of the femoral cavity may not be required, particularly in elderly patients with wide medullary canals.

After skin incision, opening the entry point with the curved awl, and positioning of the guide wire as described above, the trocar or multi-hole trocar is inserted into the reamer sleeve to protect the soft tissue during insertion. Push the trocar (use center hole, if multi hole trocar is used) and sleeve assembly down over the 3mm guide wire to the tip of the trochanter (Fig. 29 and 30).

Caution:

The one step conical reamer is a front and side cutting instrument and should be used with great care to ensure that the sharp edges of the reamer do not damage intact bone inadvertently.

Entry point optimization

The entry point can also be made without using the awl. A 3.2mm K-wire is placed through the tip of the trochanter.

If you find that the K-wire is not positioned in the optimal position, it may easily be corrected using a second K-wire in combination with the multi hole trocar.

The multi hole trocar has a special design for more precise insertion. In addition to the central hole, 4 other holes are located eccentrically at different distances from the

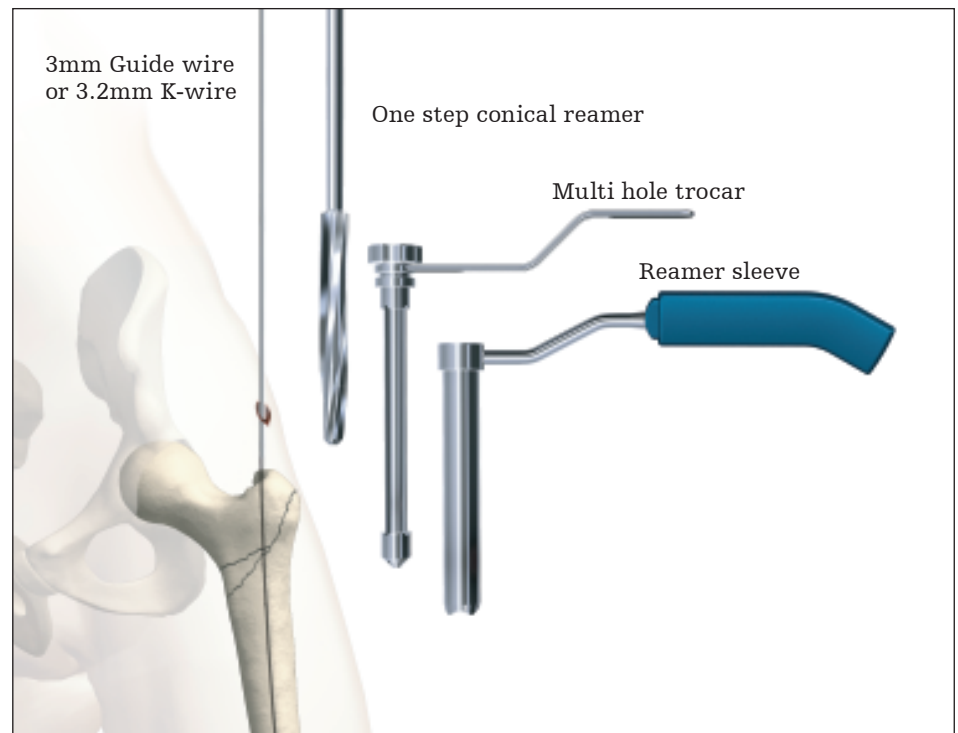


Fig. 29

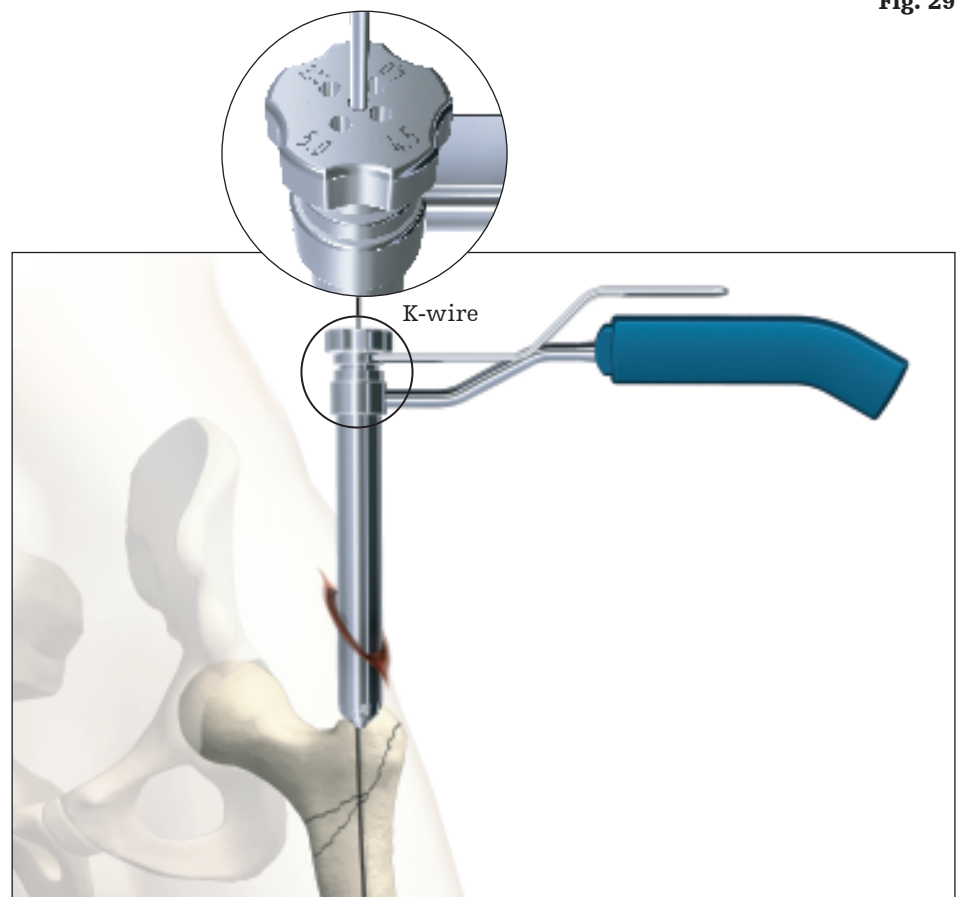


Fig. 30

Operative technique

center (Fig. 29) to easily revise insertion of the guiding K-wire in the proper position (Entry Point).

The trocar is then removed and the one step conical reamer is connected to the T-Handle and slid over the guide or K-wire to the tip of the trochanter. With gentle clockwise turning and pushing movements, the conical reamer will drill into the proximal part of the trochanter (Fig. 31 and 32) and prepare the canal for the proximal part of the Gamma3 Nail. The one step conical reamer stops when the correct depth is reached. If a 3.2mm K-wire was used it should be replaced by a guide wire now.

Caution:

3.2mm K-wires are not intended for re-use. They are single use only. K-wires may be damaged or be bent during surgical procedures. Therefore, please do NOT use the same K-wire for lag screw insertion.

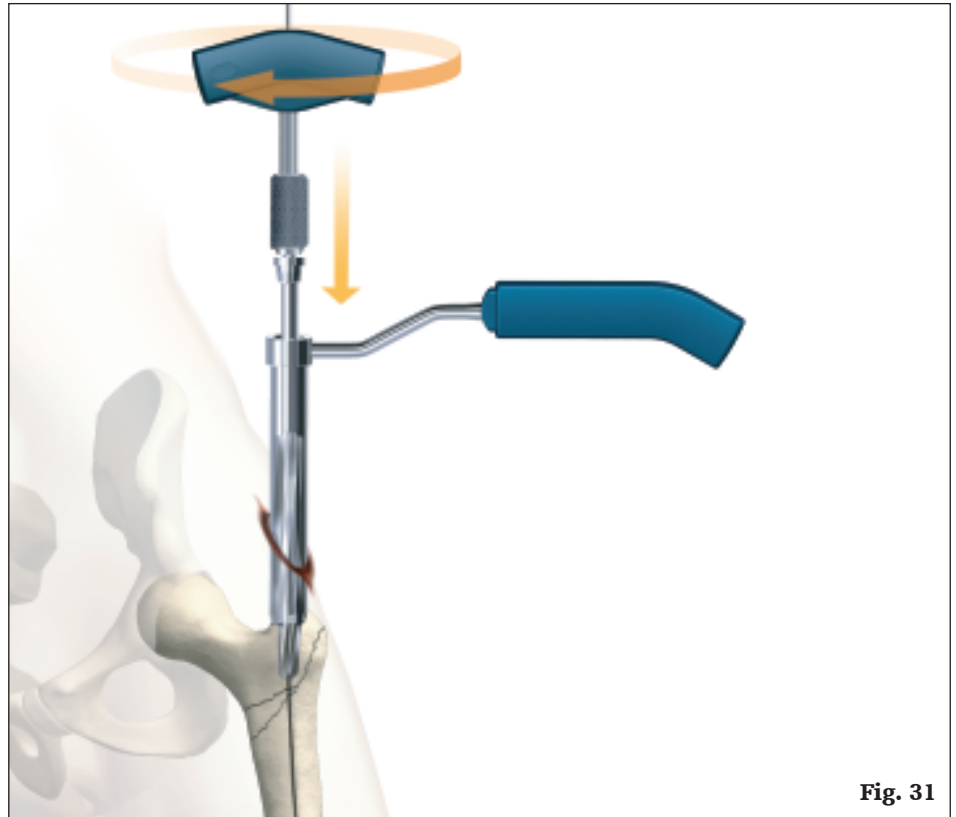


Fig. 31

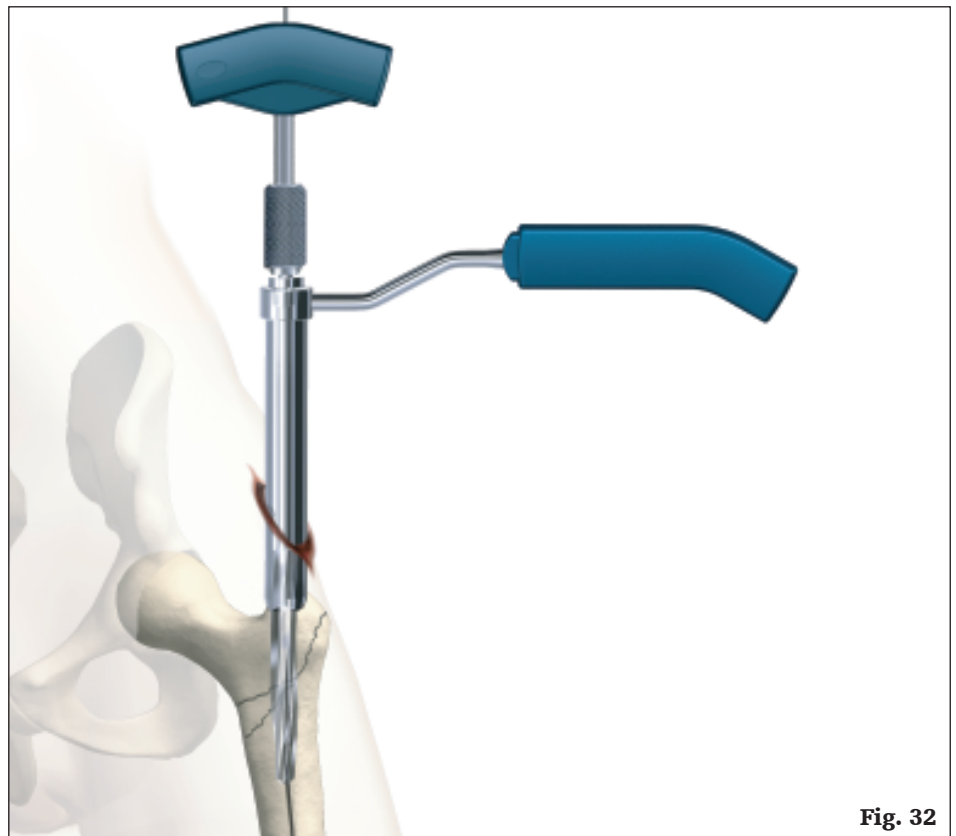


Fig. 32

Operative technique

Alternative 3: cannulated cutter

The cannulated cutter is a front cutting device used to prepare the proximal part of the femur for the Gamma3 Nail 180.

It provides surgeons with another option to open the proximal femur cavity without reaming. Especially in older patients, it may reduce the requirement for reaming of the femoral cavity.

It is guided over a solid 4mm guide pin. The fixation of this guide pin in the bone allows for an optimal placement for the cannulated cutter (Fig. 33 and Fig. 34).

This device is designed to allow for easy collection of bone graft material which might be helpful in difficult healing conditions.

Caution:

When the cannulated cutter is used, do not open the cortex with the awl, because the awl usually creates larger holes than 4mm. The 4mm guide pin needs bony stability to provide optimal cutting performance of the cannulated cutter.

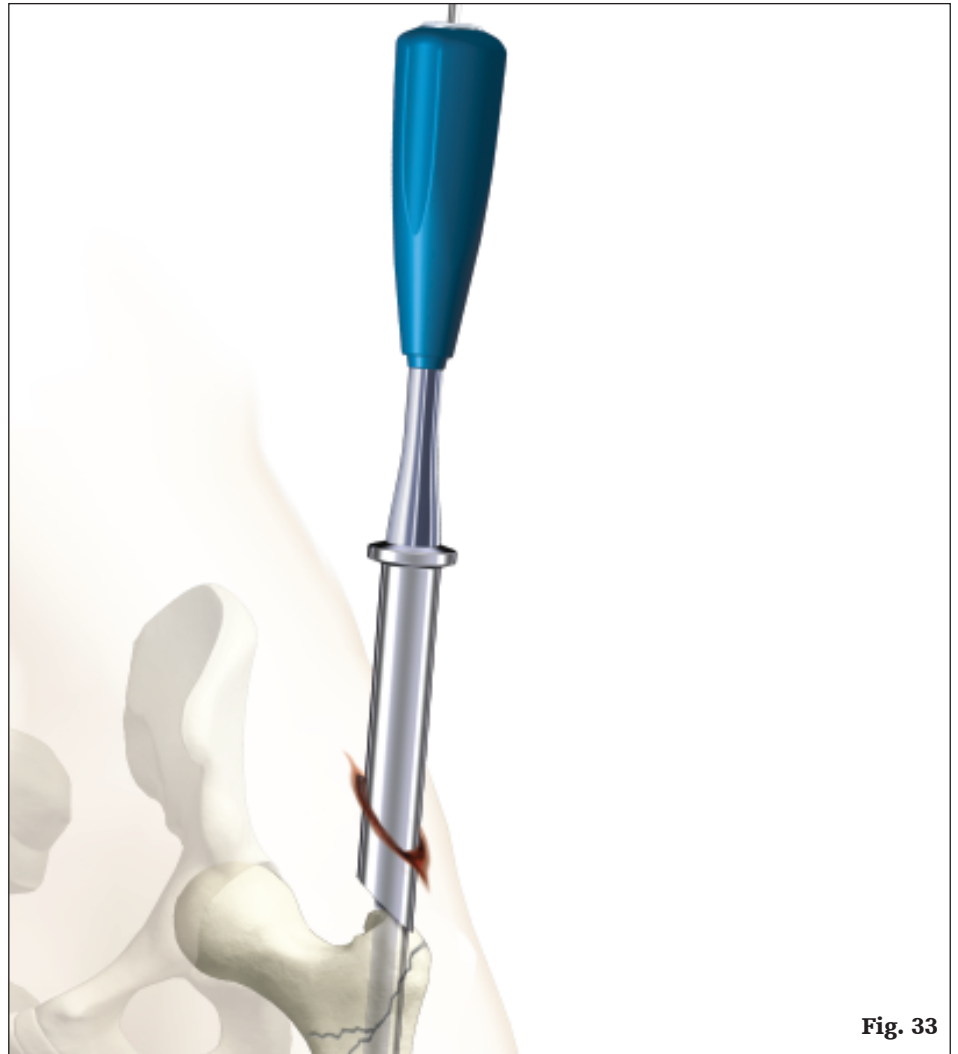

Fig. 33

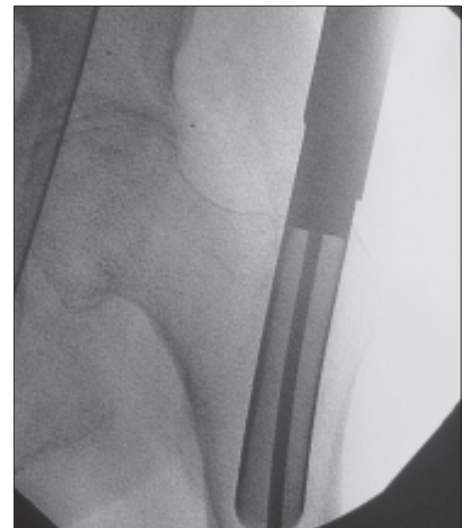
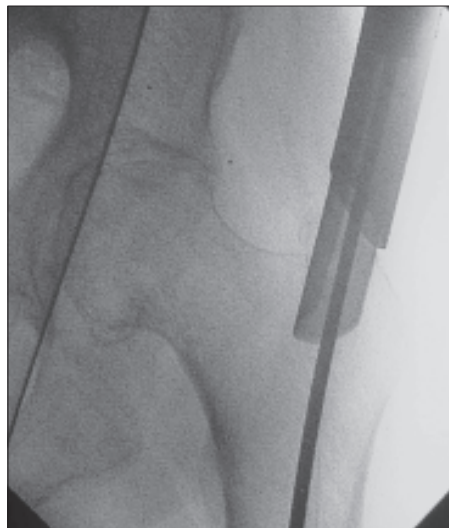
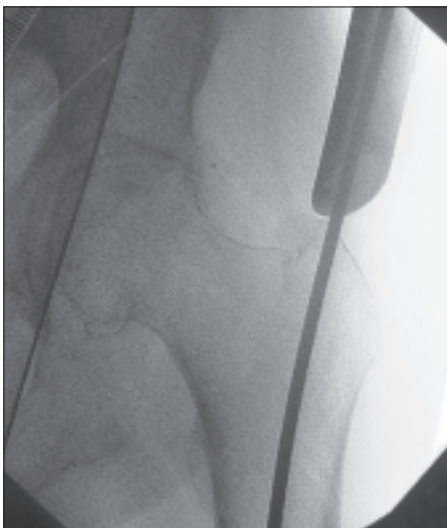


Fig. 34

Operative technique

Alternative 4: Crown drill

The crown drill is a front cutting device used to prepare the proximal part of the femur for the Gamma3 Nail 180. It may provide an option to open the proximal femur cavity without reaming. Especially in older patients, the crown drill may reduce the requirement for reaming of the femoral cavity.

Insert the K-wire with washer through a small incision using the guide wire handle until the washer reaches the surface of the greater trochanter (Fig. 35).

Then insert the assembled trocar and the reamer sleeve over the K-wire until the tip of the trocar reaches the greater trochanter (Fig. 36).

Caution:

Do not open the cortex with the awl when using the crown drill, as the awl creates a hole larger than 3.2mm. The 3.2mm K-wire needs bony stability to provide optimal crown drill cutting performance.

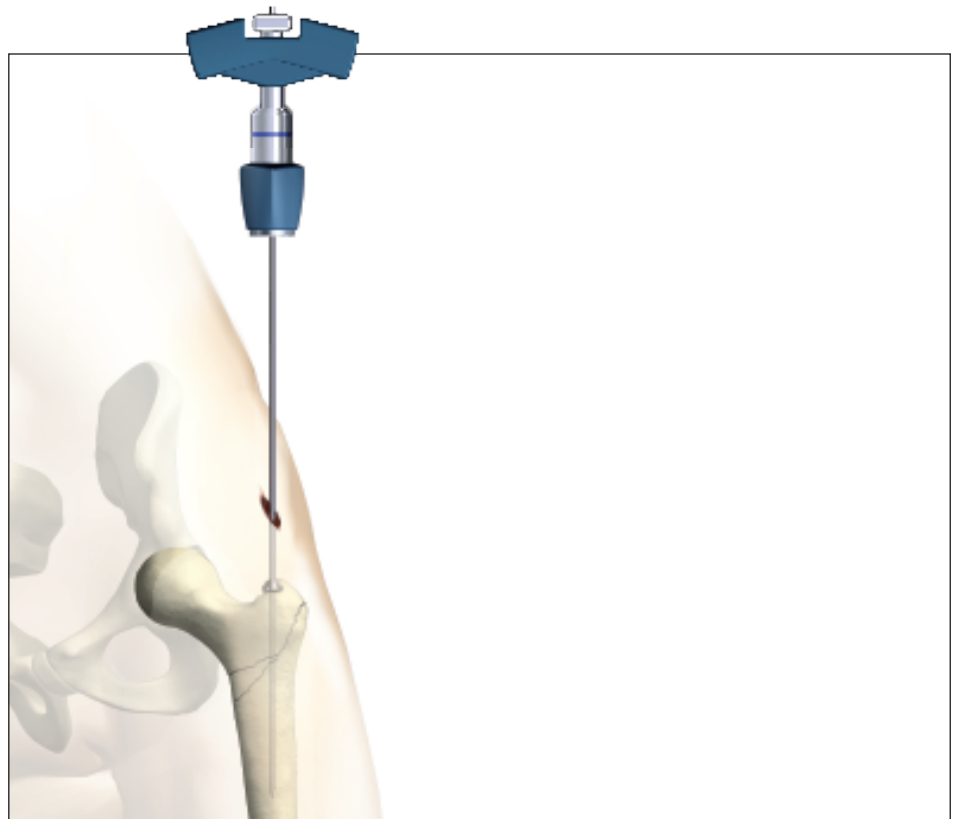


Fig. 35

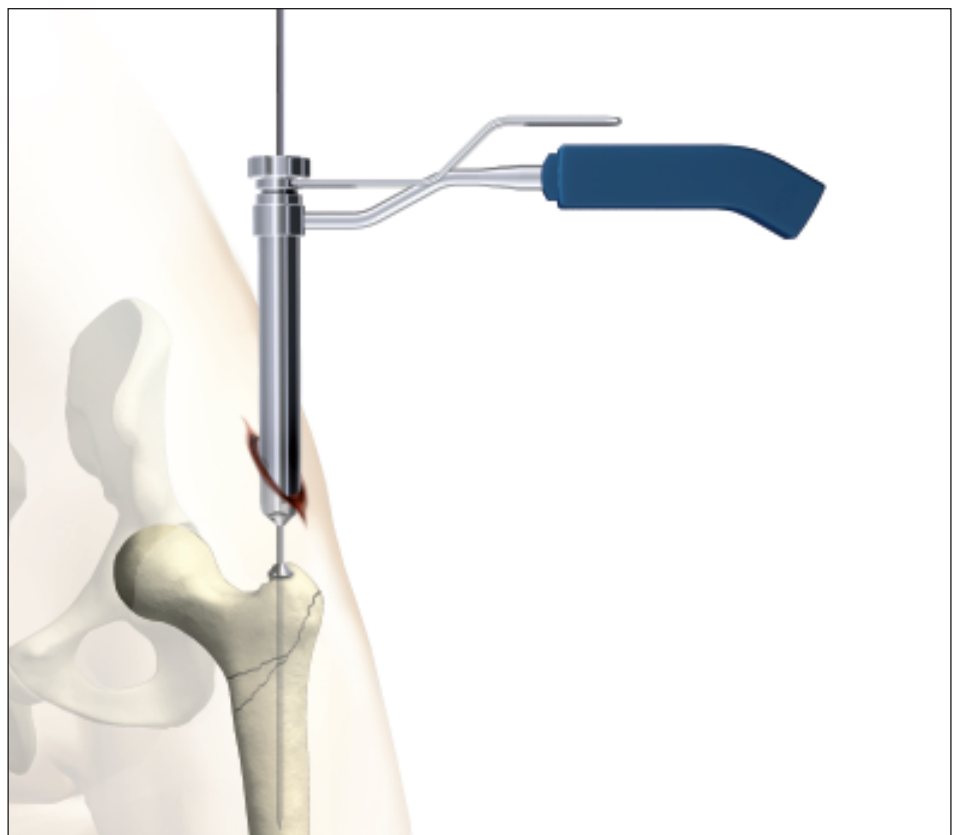


Fig. 36

Operative technique

Remove the trocar and then connect the crown drill to the T-Handle and slide it over the K-wire to the tip of the greater trochanter.

With gentle clockwise turning and pushing movements, the crown drill will drill into the proximal part of the trochanter and prepare the canal for the proximal part of the Gamma3 Nail. The crown drill stops when the correct depth is reached (Fig. 37 and 38).

Caution:

If using a power tool to drive the crown drill, particular attention must be paid to the position of the K-wire. The crown drill is a front and side cutting instrument and should be used with great care to ensure that the sharp edges of the reamer do not inadvertently ream intact bone.

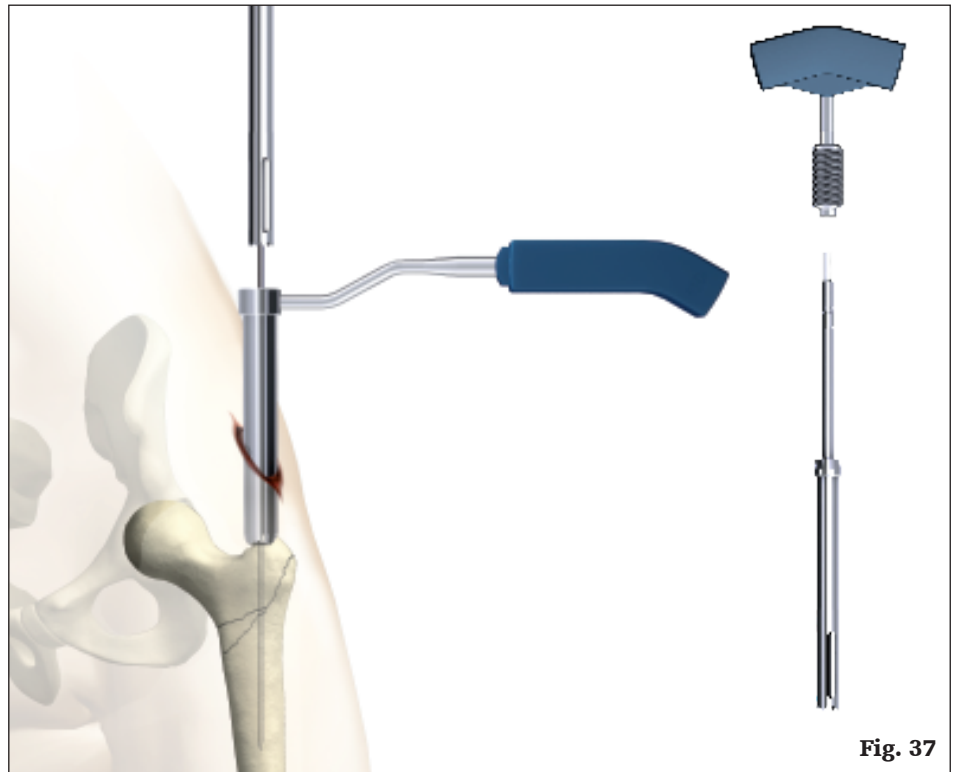


Fig. 37

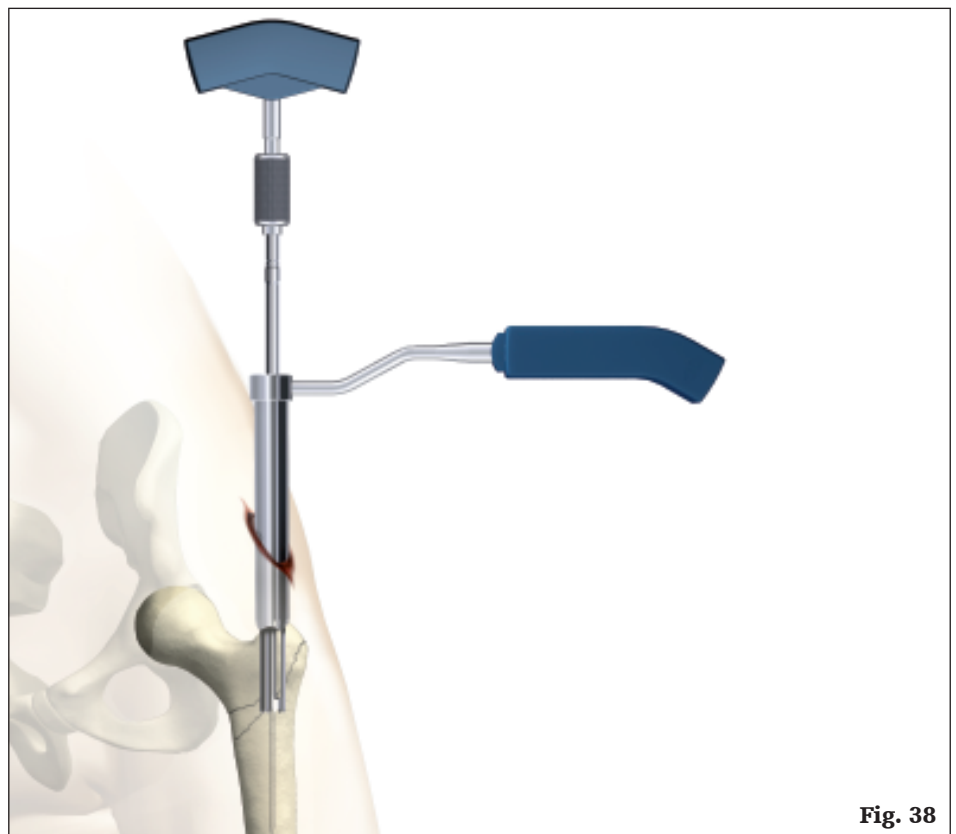


Fig. 38

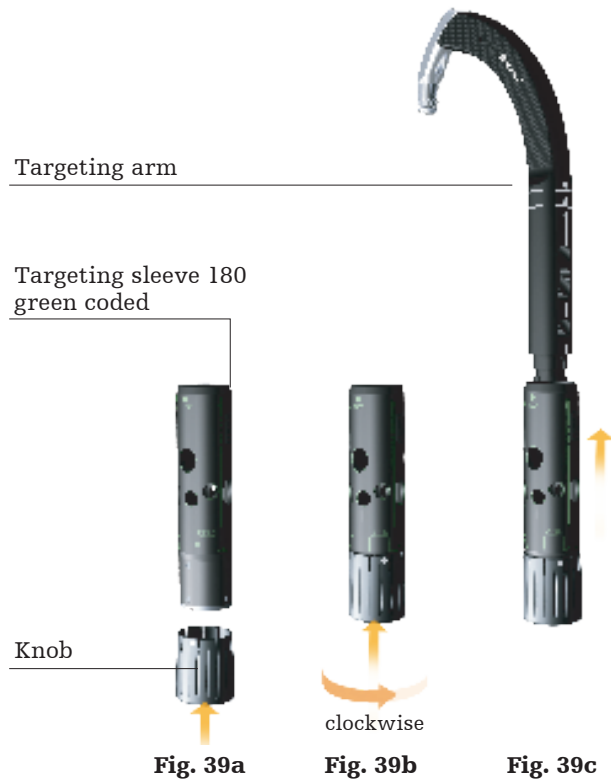Operative technique

Assembly of targeting device

1. Targeting sleeve and knob assembly

First assemble the knob to the targeting sleeve (Fig. 39a) and adjust the point on the knob to be in line with the arrow on the target sleeve. Push the knob hard against the sleeve. The knob moves approximately 5mm to the sleeve and has to be turned clockwise by approximately 30 degrees. Now release the knob and it will slip back the same distance. Now the knob is assembled to the targeting sleeve and has to be connected to the target arm (Fig. 39c).

As an alternative, the speedlock sleeve is newly available and allows for assembly of the sleeve directly to the targeting arm without going through above mentioned step. The speedlock sleeve has the same functions as the assembled targeting sleeve and knob. This operative technique describes the use with the speedlock sleeve (Fig. 39d) in the following chapters.



2. Targeting arm and speedlock sleeve assembly

Push the speedlock sleeve assembly over the targeting arm along the line until it stops (arrow line to arrow line).

Rotate the speedlock sleeve around to the required nail angle position for the lag screw, e.g. 125° (point to point) or distal locking positions, either "dynamic" or "static". Now the targeting sleeve must be fixed in this position by pushing it strongly against the targeting arm. You will feel and hear as the sleeve snaps into position.

By turning the speedlock sleeve knob into the "lock" position, the speedlock sleeve can be locked to the targeting arm. It also locks either the lag screw guide sleeve or the tissue protection sleeve.



Operative technique

3. Assembly of the targeting device and the Gamma3 nail 180

The selected Gamma3 nail is now assembled to the carbon fiber targeting device as shown in Fig. 40. The nail connecting part of the targeting device is designed with an easy assembly function for fast and secure nail fixation.

Ensure that the locating pegs fit into the corresponding notches of the proximal part of the nail.

Fully tighten the nail holding screw with the ball tip screwdriver, so that it does not loosen during nail insertion.

Before starting surgery the following functions of the targeting device have to be checked:

1. Secure fixation between nail and target device.
2. Lag screw guide sleeve matches the selected nail angle.
3. Distal locking position of the tissue protection sleeve, for required "static" or "dynamic" locking.

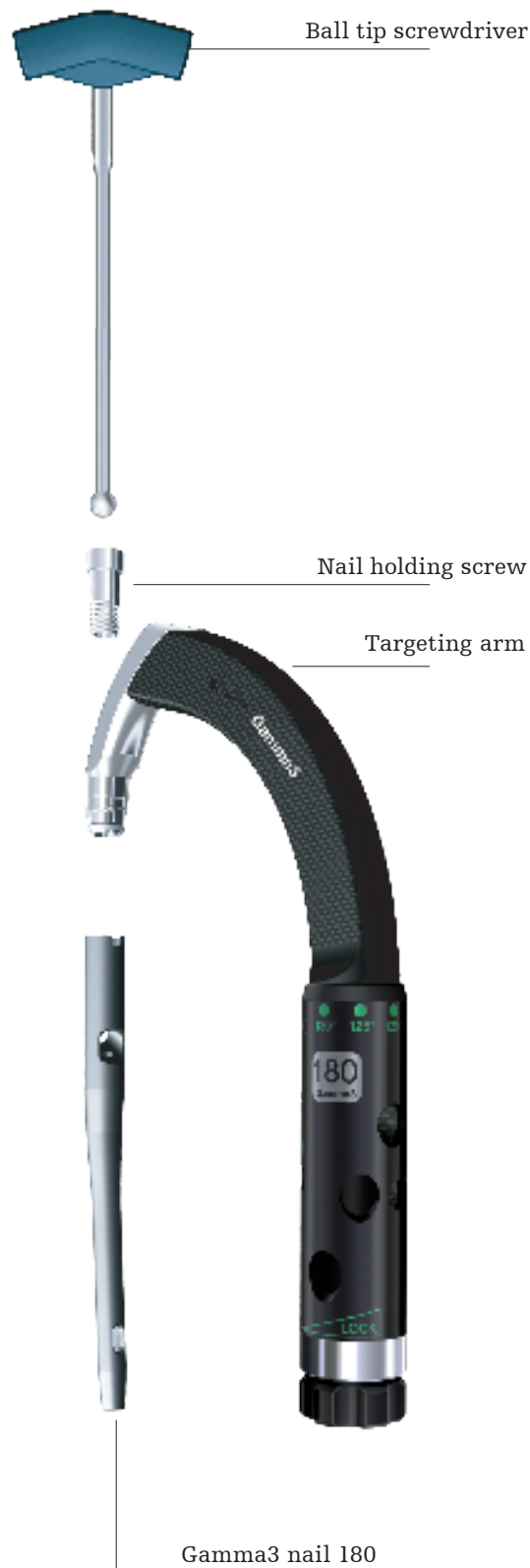

Fig. 40
Gamma3 nail assembly

Operative technique

Before checking the function of the lag screw guide sleeve or tissue protection sleeve for the distal locking, the speedlock sleeve knob must be positioned in the counter clockwise position. Pass the lag screw guide sleeve gently through the hole of the speedlock sleeve and tighten it gently in its final position by turning the knob clockwise. Check correct nail angle using the K-wire, 4.2mm drill or lag screw step drill (Fig. 41).

Remove the lag screw guide sleeve in the opposite order; turn the speedlock sleeve knob counter-clockwise and remove the lag screw guide sleeve by pulling it back.

Before the distal locking function can be checked, the speedlock sleeve has to be positioned in either the "static" or "dynamic" mode.

Pull the speedlock sleeve back and turn the sleeve until the required distal locking position is reached. Now push the sleeve against the target arm until a "snap in" is felt.

The distal tissue protection sleeve is passed through the speedlock sleeve until its final position is achieved. Lock the distal tissue protection sleeve by gently turning the speedlock sleeve knob clockwise. Check position with the drill sleeve and 4.2mm drill (Fig. 41a).

Note:

Before starting surgery, the implant and instrument assembly must be checked. Ensure that the sleeve angle matches the corresponding nail angle chosen, e.g. a 125° nail, and the distal sleeve matches either for "dynamic" or "static" locking as required (Fig. 41 and 41a).

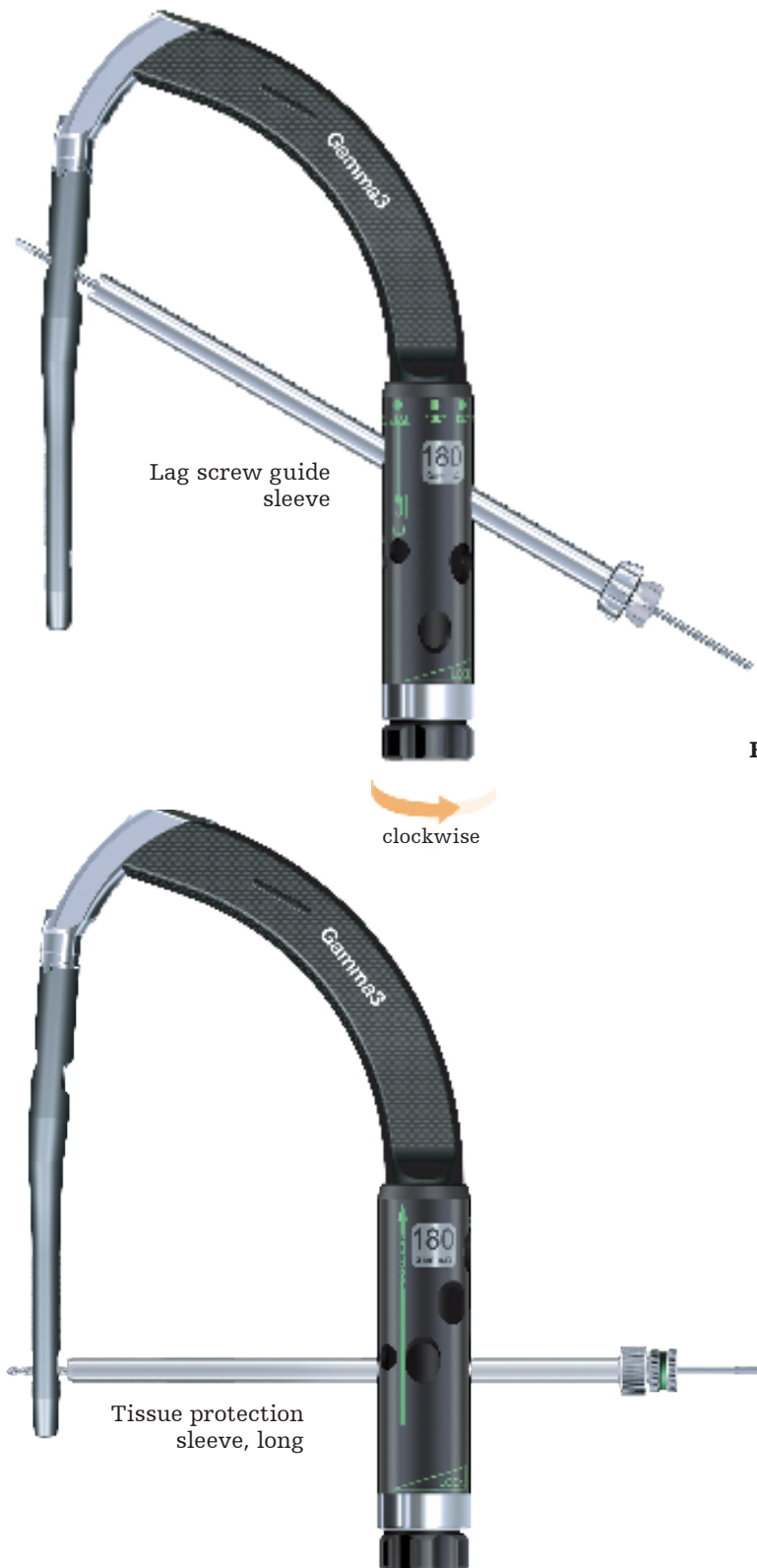

Fig. 41

Fig. 41a

Checking of lag screw sleeve and distal locking sleeve positioning and function.

Operative technique

Nail insertion

The nail is advanced through the entry point passing the fracture site to the appropriate level.

If dense bone is encountered, first re-evaluate that sufficient reaming has been achieved, then, if necessary, the strike plate can be attached to the targeting arm and the slotted hammer may be used to further insert the nail (Fig. 42).

More commonly, the nail is positioned too proximal and correction of the nail should be carried out either by hand or by using the strike plate placed into the target device. If a higher position is required, the universal rod and slotted hammer may then be attached to the strike plate to carefully and smoothly extract the assembly. The new position is checked again with the image intensifier as described above.



Fig. 42

Danger:

The nail must progress smoothly, without excessive force. If too much resistance is encountered, removal of the nail and additional reaming is recommended.

Note:

Remove the guide wire prior to drilling or K-wire insertion.

Final seating with impactor

The carbon fiber guide should never be struck as it may break or become deformed. The impactor that is provided can be utilized to assist with final seating of the nail. Gentle tapping will produce small adjustments (in the nail position) that can help to optimize the ultimate position of the lag screw in the femoral head. The nail holding screw should be re-tightened following any use of the impactor.

The impactor should not be utilized to force the nail down the canal. If the nail cannot be seated manually or if there is no advancement each time the impactor is tapped, A/P and lateral fluoroscopic X-rays should be reviewed to determine the cause of the impingement - there may be a mismatch

between the nail geometry and the medullary canal. The starting position, the femoral bow and the canal diameter should all be examined to ensure that the leading end of the nail is not impinging on the medial or anterior cortex and that the canal itself has been sufficiently reamed.

Periodically, nail removal and further reaming of the diaphysis may be required.

The proximal metaphyseal flair may be undersized (particularly in young patients or those of short stature) and serve to prevent nail advancement. If this situation is encountered, a flexible reamer may be used to further widen this area to the level of lesser trochanter.

To facilitate manual passage, the nail should be rotated 90° internally until the fracture has been passed.

Operative technique

The final nail depth position is monitored with the image intensifier C-arm; the projected axis of the lag screw may be projected with a ruler on the monitor screen to ensure that the lag screw is placed in the optimal position.

Proceed until the axis of the lag screw hole (visible as a crescent shape on the screen) is aligned with the lower half of the femoral neck (Fig. 43). The objective of this is to ultimately position the lag screw centrally or slightly inferior in femoral head in the frontal plane.

Note:

Remove guide wire for the flexible reamer and nail insertion using guide wire handle.

When the Gamma3 Nail has been inserted to its final depth, check the anteversion of the nail. By using of the K-wire Clip or closed tube clip with K-wires (Fig. 44). As an alternative the Gamma3 U-Wire can be used with the K-wire Clip or closed tube clip.

The K-wire clip or closed tube clip is mounted into the slots of the target arm by pressing the clip flanges together.

Caution:

Before proceeding ensure that the nail holding screw is still fully tightened.

The lag screw should be placed in the central position of the femoral head in the lateral view (Fig. 45).

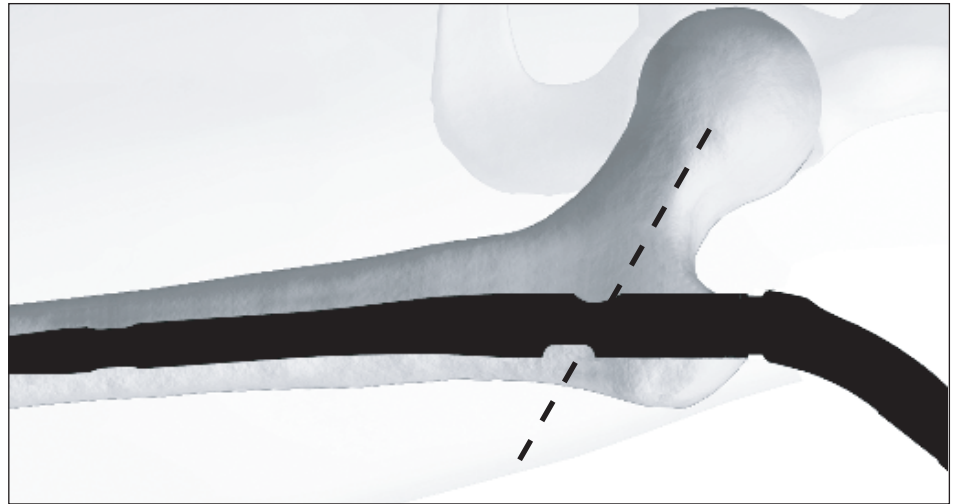


Fig. 43



Fig. 44



Fig. 45

Operative technique

Lag screw positioning using the one shot device

The one shot device is recommended for establishing whether the lag screw is in the optimum position. This device is designed to enable correct positioning of the K-wire for lag screw placement before performing lateral skin incision and opening of the lateral cortex (Fig. 46–47a).

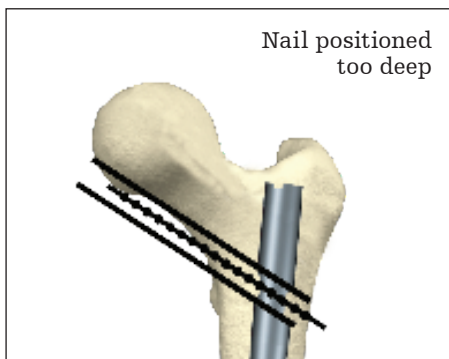
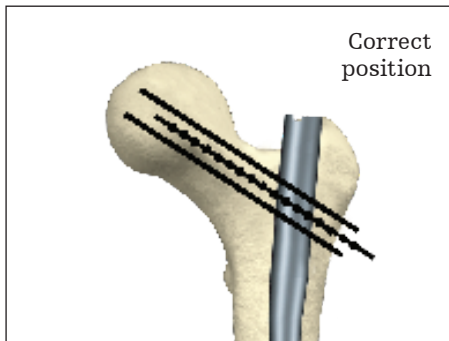
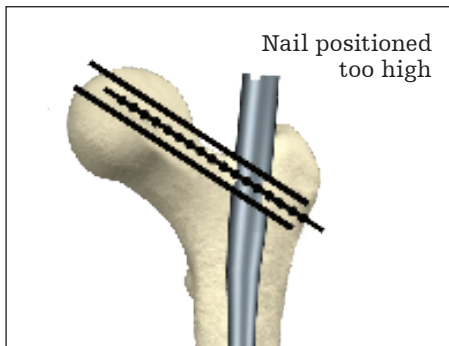


Fig. 46a
A/P view

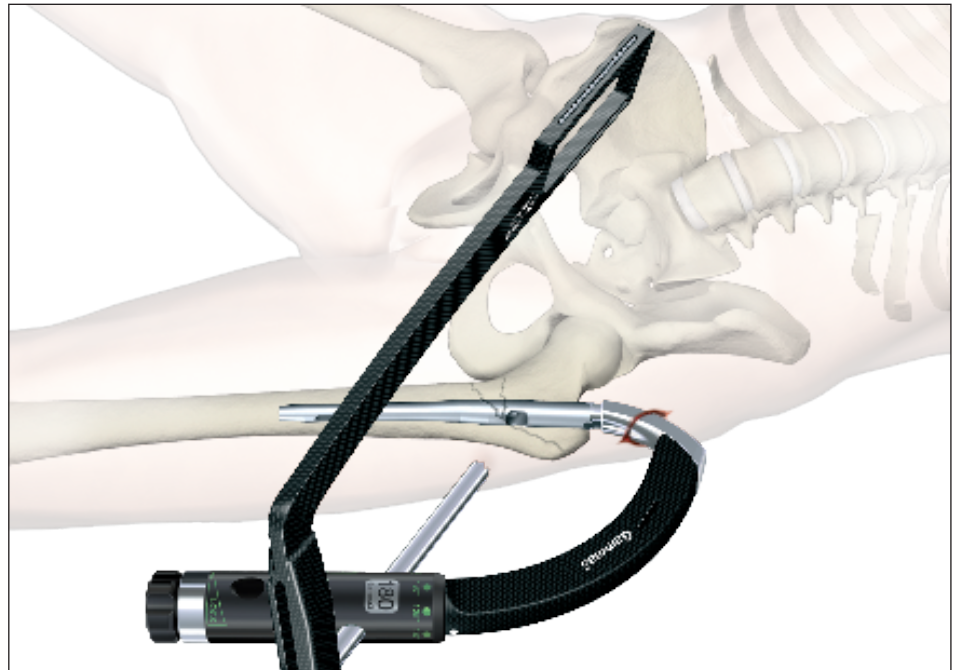


Fig. 46
Positioning of nail depth




Fig. 47
Positioning of anteversion




Fig. 47a
Lateral view

Operative technique

Lag screw insertion

The targeting device may be held by an assistant to prevent its weight from externally rotating the nail until the next stage is completed.

Next, assemble the lag screw guide sleeve with the green coded 4.2mm lag screw drill guide sleeve and pass them through the targeting sleeve to the level of the skin. This indicates the position for a small incision down to the bone (Fig. 48). The guide sleeve assembly is now advanced through the incision. If the guide catches the fascia lata, twisting it will usually allow it to pass through to the bone.

In order to facilitate the smooth insertion of the sleeve assembly, the paddle tip trocar can optionally be used prior to the use of the lag screw drill guide sleeve. Assemble the lag screw guide sleeve with the paddle tip trocar and pass them through the targeting sleeve to the level of the skin. Make the skin incision down to the bone (Fig 48a). When the tip of the paddle trocar catches the fascia lata, twist it manually. There is a mark at the head of the paddle tip trocar that provides the direction of the trocar tip. When the tip reaches the bone, replace the paddle tip trocar to the green coded 4.2mm lag screw guide sleeve and prepare for the next pre-drilling step.

For an accurate lag screw length measurement, the outer guide sleeve must be in good contact to the lateral cortex of the femur. The knob of the target sleeve must be turned gently clockwise to lock the guide sleeve in place and further stabilize the targeting assembly (Fig. 49 and 49a).

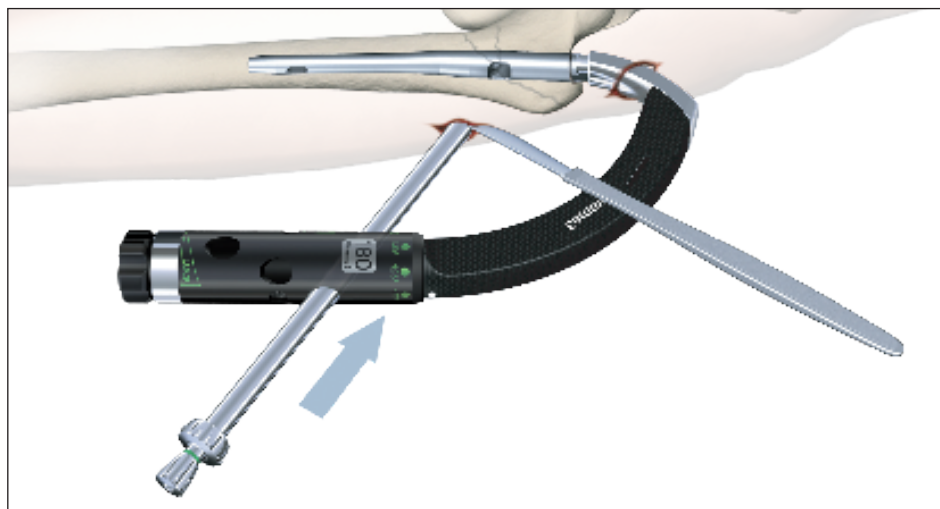


Fig. 48

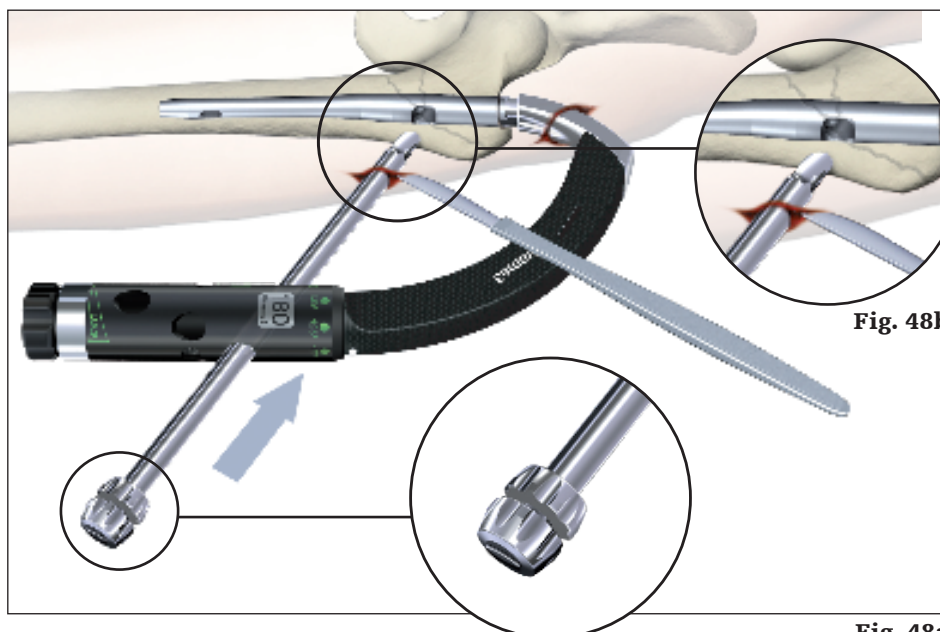


Fig. 48a

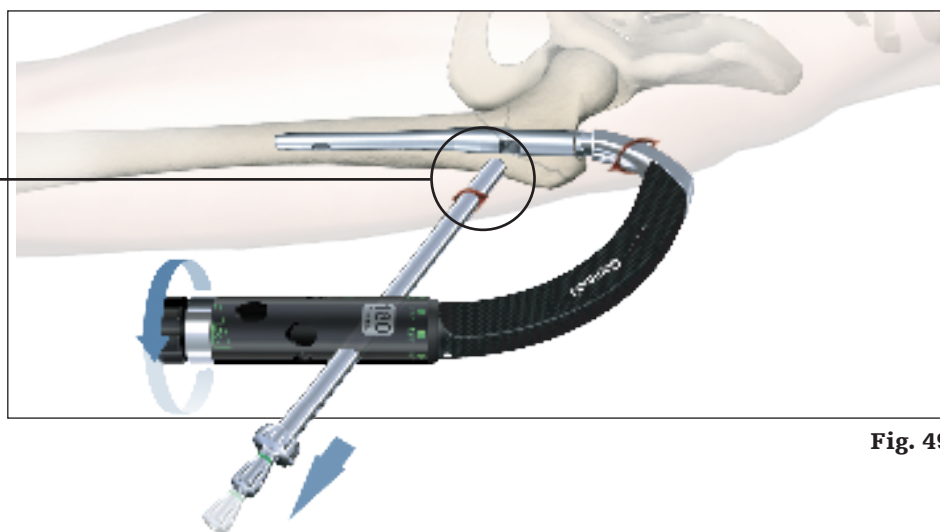


Fig. 49

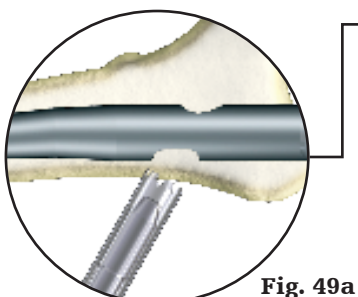


Fig. 49a

Operative technique

Pre-drilling the lateral cortex

With the lag screw guide sleeve firmly engaged in the cortex, the green coded 4.2mm lag screw drill guide sleeve should be pushed gently against the cortex. Using the green coded 4.2mm × 300mm center tipped drill, the lateral cortex should be opened by power tool or by hand. A longer 4.2mm × 360mm drill is also available as an alternative for deeper pre-drilling possibility, allowing for a longer guidance for the K-wire (Fig. 50).

The green coded 4.2mm lag screw drill guide sleeve is then replaced by the K-wire sleeve. (Both sleeves look similar, but have different inner hole diameters. The K-wire Sleeve has no colored ring).

Note:

Before proceeding, check that the guide wire for the flexible reamer and nail insertion used earlier has been removed.

The single use K-wire inserted through the K-wire sleeve should be advanced up to the subchondral bone (Fig. 51), using the guide wire handle or using a power tool. Check that the K-wire is placed either central or in the lower half of the femoral head in the frontal plane and on the midline in the lateral plane (Fig. 51a).

Caution:

Pre-drilling offers a possibility to open the lateral cortex for the K-wire entry. Pre-drilling helps to prevent a possible slipping of the K-wire on the cortex and may avoid deflection within the femoral head. This helps to perform the lag screw reaming without nail contact. Therefore check the proper K-wire position with the image intensifier in both the anterior-posterior and mediolateral views as shown in Fig. 43 and 45 to ensure that K-wire deflection did not occur.

Warning:

In the event the nail is damaged during lag screw reaming, the fatigue strength of the implant may be reduced which may cause nail to fracture.




Fig. 50
Opening of the lateral cortex

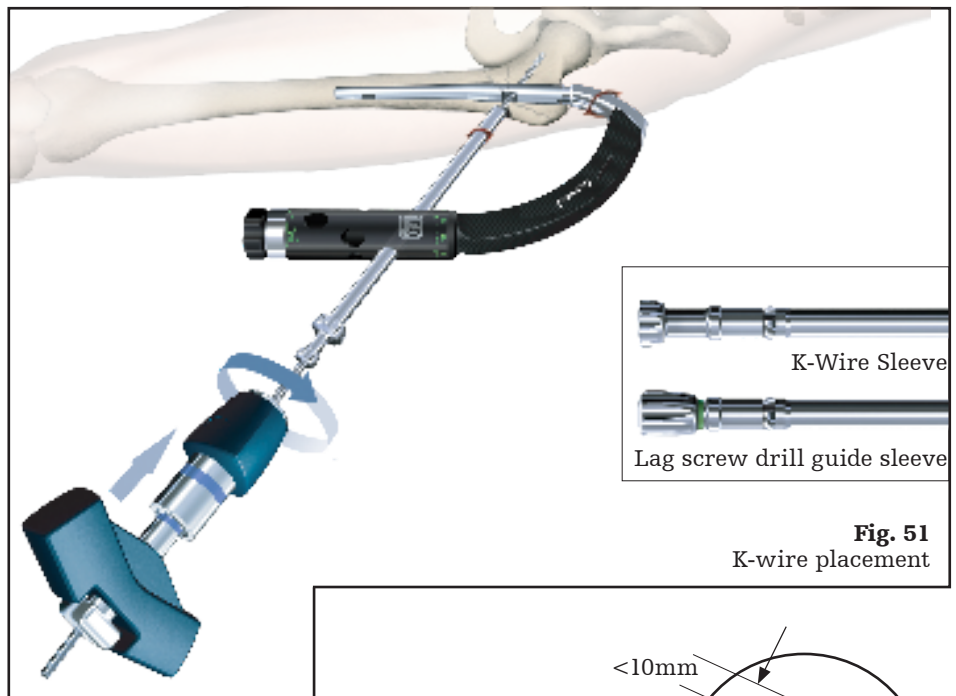


Fig. 51
K-wire placement

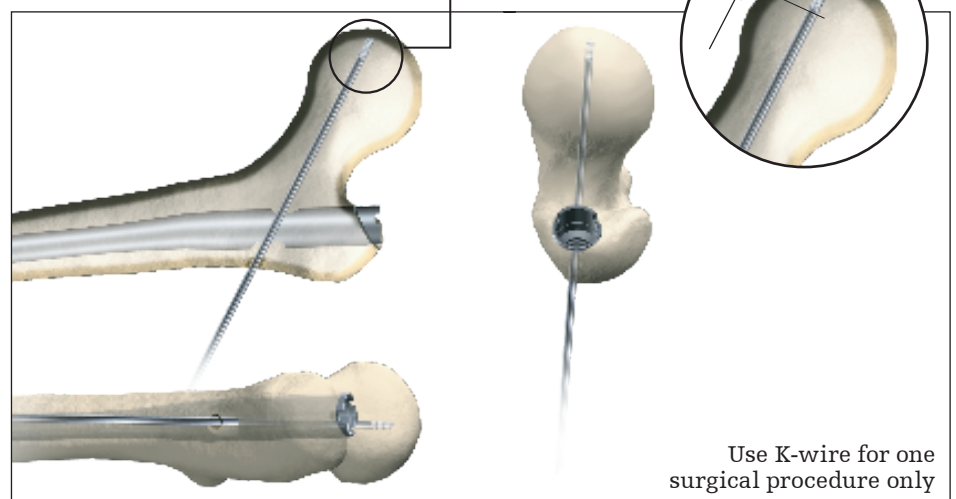


Fig. 51a
K-wire placement

Operative technique

Lag screw insertion

The objective is to position the lag screw either in the center or below the center of the femoral head in the anterior-posterior view and centrally in the lateral view, to provide the best load transfer to the lag screw (Fig. 52).

After satisfactorily positioning the K-wire, the required lag screw length is measured using the lag screw ruler.

Before starting to measure, ensure that the lag screw guide sleeve is still pressed firmly against the lateral cortex of the femur (Fig. 52a).

Place the lag screw ruler directly under the K-wire (Fig. 53).

The recommended value for the step drill depth and the lag screw length can be read directly from the lag screw ruler. If the value is between markings on the scale, e.g. 97mm, it should always be rounded up to the next higher value, e.g. 100mm.

Warning:

K-wires are not intended for re-use. They are single use only. K-wires may be damaged or bent during surgical procedures. If a K-wire is re-used, it may get stuck in the drill and could be advanced into the pelvis, and may damage large blood vessels or cause other serious injuries.

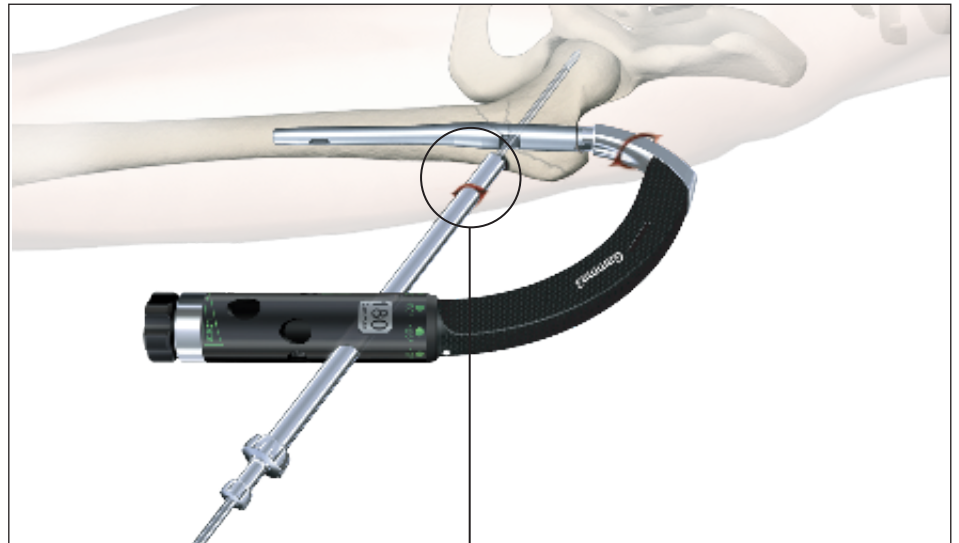


Fig. 52
Lag screw length measurement

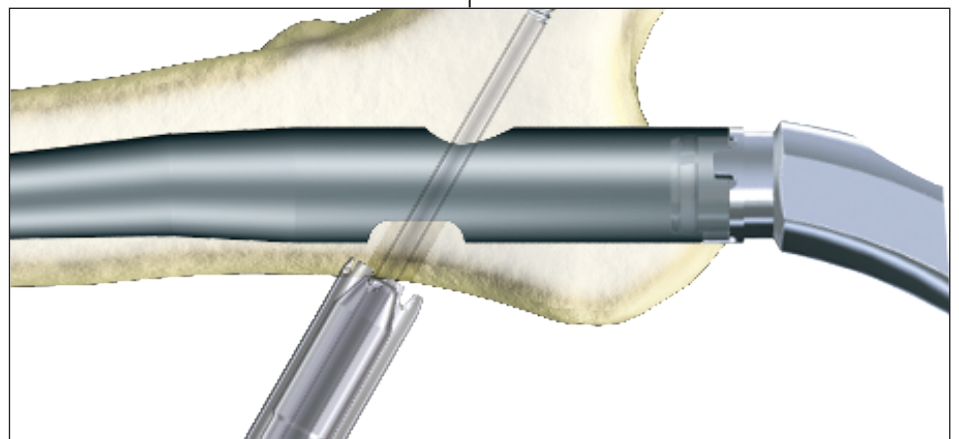


Fig. 52a

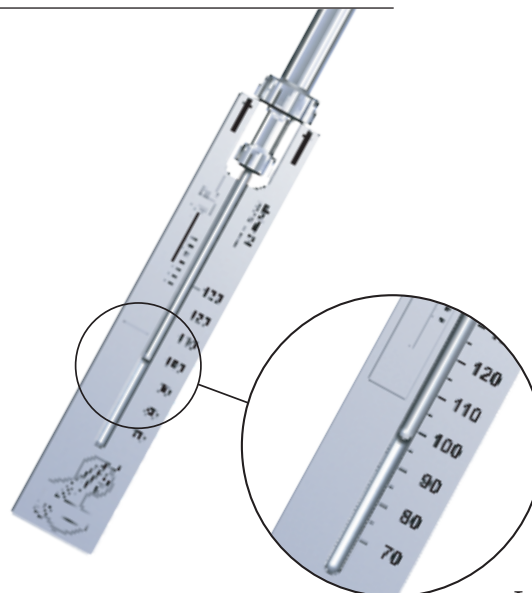


Fig. 53
Lag screw length measurement

Operative technique

The value of the measurement (Fig. 53) is now transferred to the adjustable stop on the lag screw step drill (Fig. 54). The value e.g. 100 must be visible in the window (Fig. 54a).

The K-wire sleeve is now removed and the adjusted lag screw step drill is passed over the K-wire (Fig. 55), through the lag screw guide sleeve.

The channel for the lag screw is prepared using the T-Handle connected to the lag screw step drill. A power tool may be used with great care paying specific attention to the K-wire position.

Drilling should continue until the stop of the step drill comes into contact with the lag screw guide sleeve (Fig. 56). Ensure that the targeting device is well supported to prevent it from slipping back or rotating.

The drilling process, especially when the tip of the drill comes close to its final position in the femur head, should be controlled under an image intensifier to avoid hip joint penetration. The K-wire also may be observed in the K-wire window of the step drill.

Warning:
It is important to observe the K-wire tip during drilling on the intensifier. The K-wire window provides an additional possibility to double check the K-wire end position.

Ensure that under no circumstances the K-wire is advanced into the pelvis. In case a deflection of the K-wire is observed, it is strongly recommended to remove the K-wire and replace it with a new one. If the stepdrill does not pass through the lag screw hole with ease, check by image intensifier whether the K-wire is deflected or not. Never drive the stepdrill with force through the nail, since this may cause severe damage to the nail and increased risk of implant failure.



Fig. 54

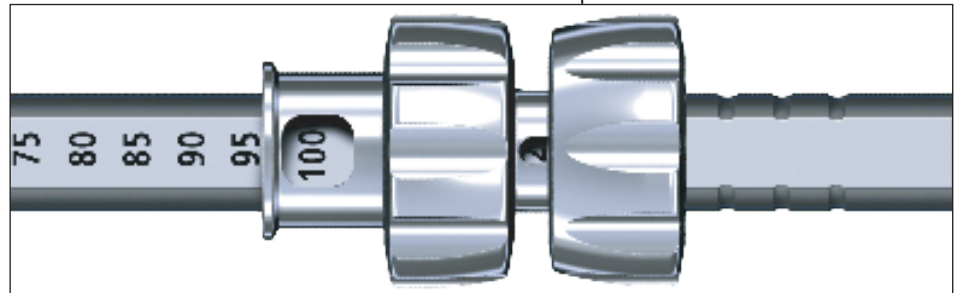


Fig. 54a

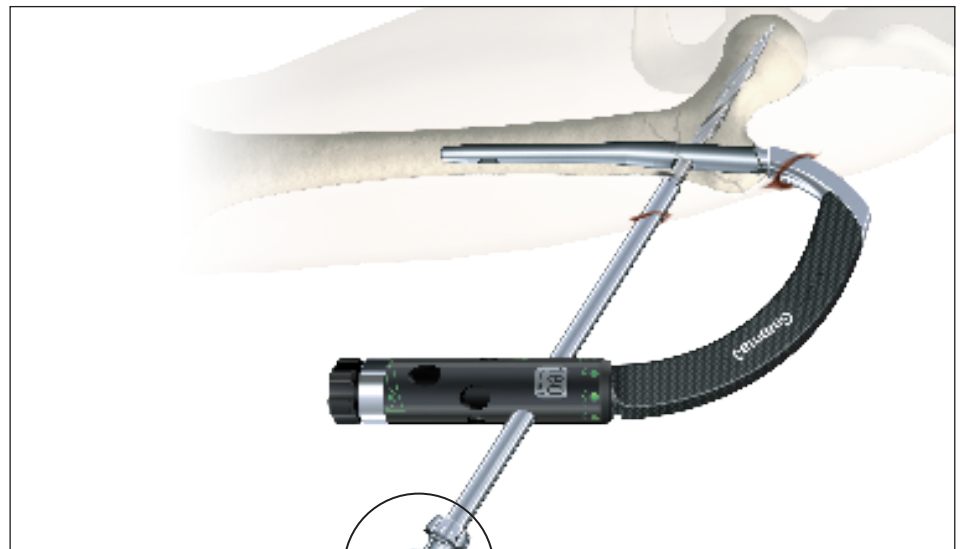


Fig. 55

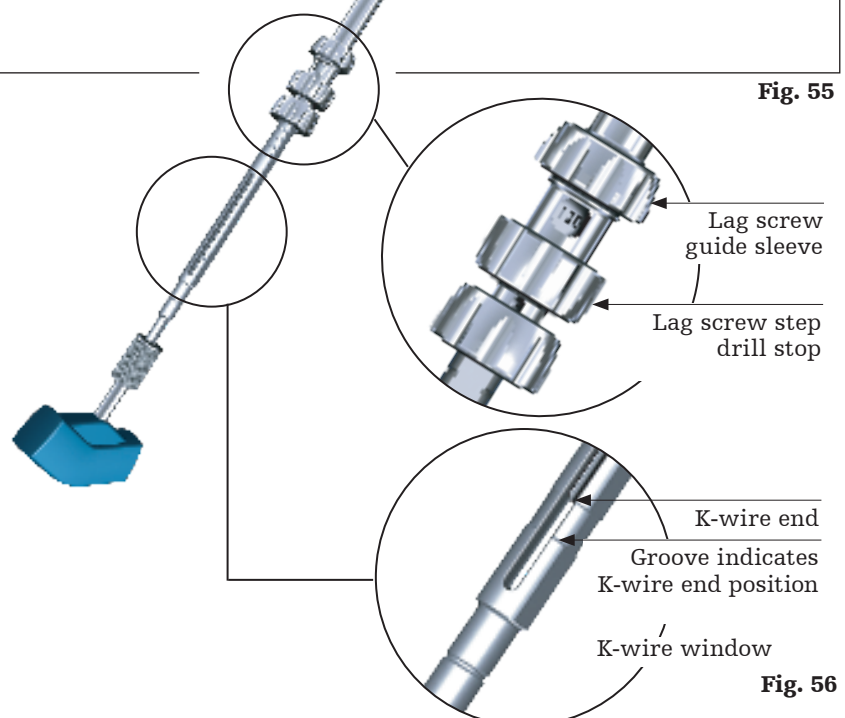


Fig. 56

Operative technique

Lag screw insertion

Check on the image intensifier during drilling to monitor the depth of the drill near the subchondral bone.

At this stage, you should see the tip of the K-wire protruding about 6 to 10mm out of the step drill. This is because the threaded portion of the K-wire was intentionally not included in the drill measurement. This is to prevent the drill from penetrating the joint (Fig. 57) and to ensure that the K-wire remains anchored in the subchondral bone after reaming. Remove the Step Drill by turning it clockwise and pulling it backwards.

In case of the hard bone, the lag screw Tap is available as an option.

Transfer the value of the measurement (Fig. 53) to the adjustable stop on the lag screw tap (Fig. 57a). Make sure that the value (e. g. 100) is visible in the window (Fig. 57b). The selected length of the step drill, the lag screw tap and the lag screw should all be the same (in this example 100mm).

The screw is then assembled to the lag screwdriver (Fig. 58).

In a case where compression is to be applied, a shorter lag screw length should be chosen to avoid the excessive lateral lag screw protrusion (see chapter compression/ apposition instructions below). Ensure that the pins of the lag screwdriver are in the slots of the lag screw. The end thumbwheel must be turned clockwise and tightened using the ball tip screwdriver.

The lag screw assembly is now passed over the K-wire, through the lag screw guide sleeve, and threaded up to the end of the pre-drilled hole of the femur head. Check the end position of the lag screw on the image intensifier. A double check of the end position is also possible with the indicator ring (Fig. 58a) on the lag screw screwdriver when it reaches the end of the lag screw guide sleeve.

Warning:

Make sure that the K-wire does not protrude into the pelvis during the lag screw insertion.

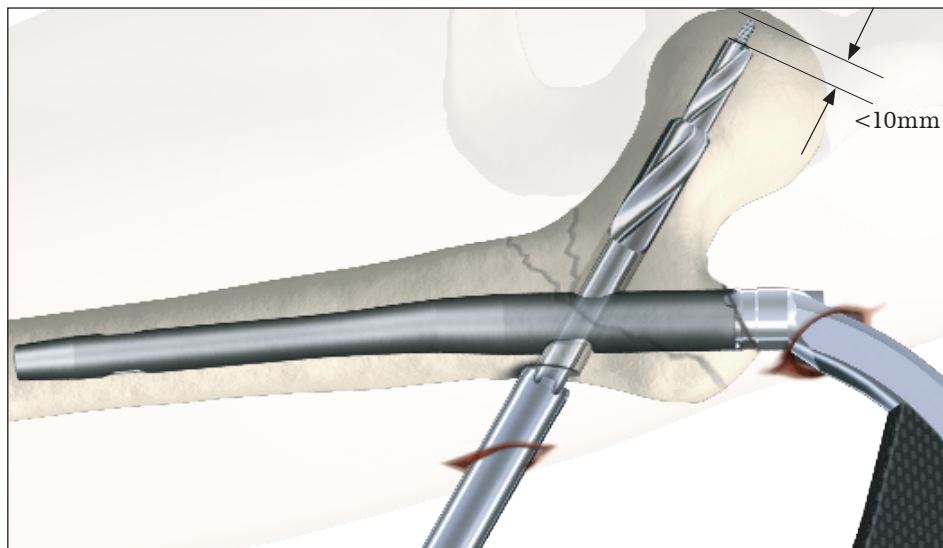


Fig. 57



Fig. 57a

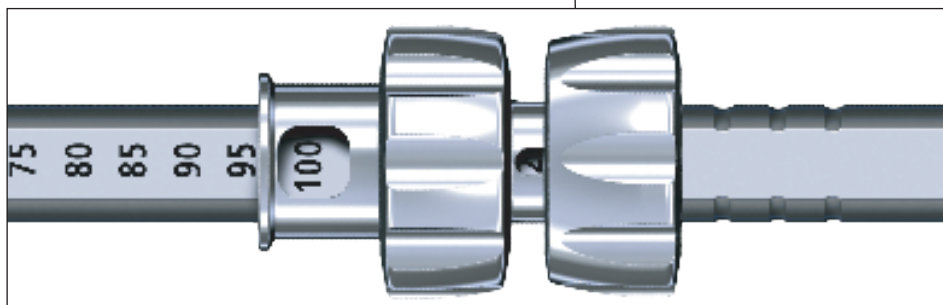


Fig. 57b



Fig. 58

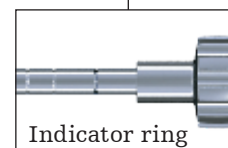


Fig. 58a

Operative technique

Lag screw fixation

The handle of the lag screwdriver must be either parallel or perpendicular (90°) to the target arm (Fig. 60 and 60a) to ensure that the set screw is able to fit into one of the 4 grooves of the lag screw shaft. The set screw alignment indicator will help to find the right position of the handle.

If the T-Handle is not perpendicular or parallel to the target arm, turn it clockwise until it reaches this position. NEVER TURN THE LAG SCREW COUNTER CLOCKWISE.

If the K-wire is inadvertently removed, then the screw may still be inserted without it, provided that the guide sleeve is still in contact with the cortex.

Warning:

It is strongly recommended to place the lag screw at the end of pre-drilled hole in order to provide maximal resistance against cut-out. Never turn the lag screw counterclockwise after the final position is reached, because otherwise the lag screw may lose full bony surface contact to its tip.

Compression / apposition

If compression or apposition of the fracture gap is required, this can be achieved by gently turning the thumb-wheel of the lag screwdriver clockwise against the guide sleeve (Fig. 59). In osteoporotic bone care must be taken to prevent lag screw pullout in the femoral head. The lag screw should be chosen shorter depending on the expected amount of compression.

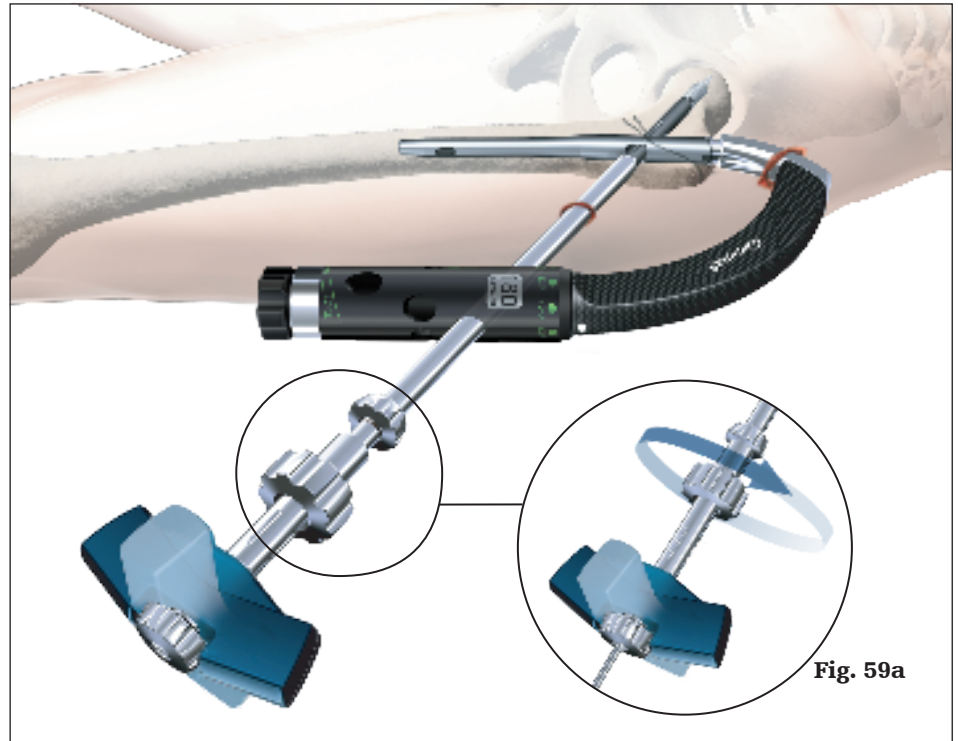
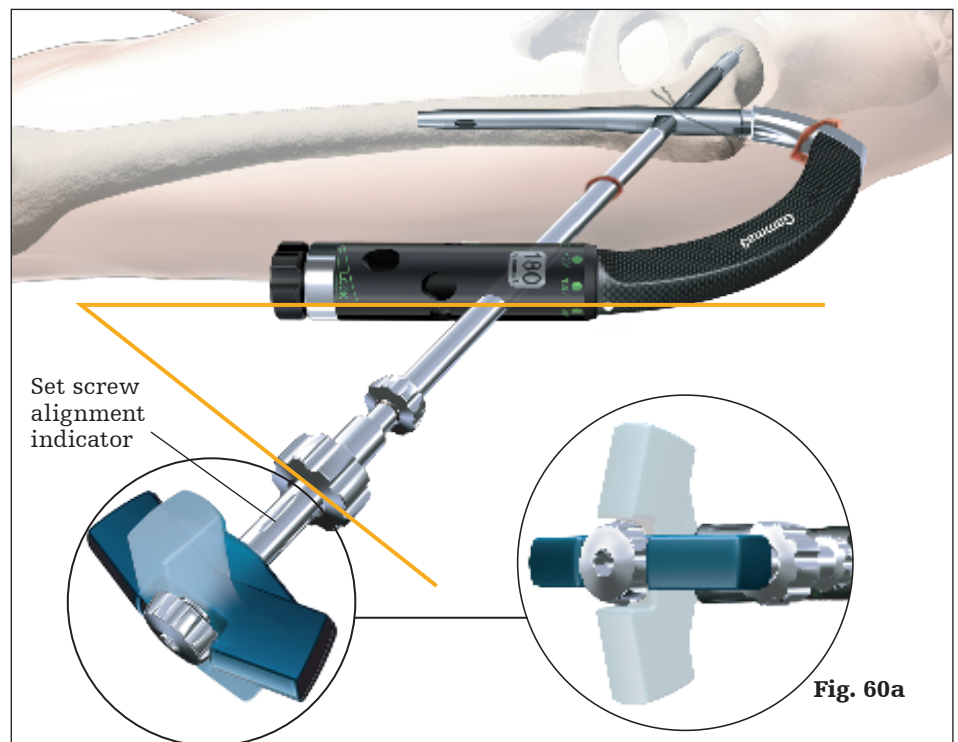


Fig. 59a

Fig. 59



Set screw
alignment
indicator

Fig. 60a

Fig. 60
T-Handle end position

Operative technique

Set screw insertion

Caution:

**The set screw must be used.
The use of the set screw is not optional.**

Assemble the set screw to the set screw driver. Insert the set screw as shown in Figure 61 along the opening of the post of the targeting device and advance it through the nail holding screw pushing the set screwdriver.

Push the set screw driver down until you are sure that the set screw engages the corresponding thread in the nail. During pushing down the assembly, you may feel a slight resistance.

Turn the screwdriver handle clockwise under continuous pressure. You may notice a resistance when turning the set screw. This is because the set screw thread is equipped with the “nylstop” system to prevent spontaneous loosening.

This is not the final position for the set screw. Keep turning the set screw until you feel contact in one of the grooves of the lag screw.




Fig. 61
Set screw insertion

Operative technique

Lag screw fixation

To verify the correct position of the set screw, try to turn the lag screwdriver gently clockwise and counterclockwise. If it is not possible to turn the lag screwdriver, the set screw is engaged in one of the grooves. If the lag screw driver still moves, recorrect the handle position and tighten the set screw again until it engages in one of the four grooves.

After slightly tightening the set screw it should then be unscrewed by one quarter ($\frac{1}{4}$) of a turn, until a small play can be felt at the lag screwdriver. This ensures a free sliding of the lag screw.

Make sure that the set screw is still engaged in the groove by checking that it is still not possible to turn the lag screw with the lag screwdriver.

Note:

Do not unscrew the set screw more than $\frac{1}{4}$ of a turn.

As an alternative, the set screw can be inserted using Gamma3 closed tube clip (see next page).

If distal locking is not indicated, the end cap should be assembled to the nail end to prevent bone ingrowth. Leaving the lag screwdriver in place, the nail holding screw is now removed using the ball tip screw driver or universal socket wrench and turning it counter clockwise. insert the end cap (size 0) using the socket wrench or the ball tip screwdriver. The end cap should be tightened slightly.

Please see chapter "end cap insertion". Alternatively the end cap could also be inserted free hand after removal of the target device.

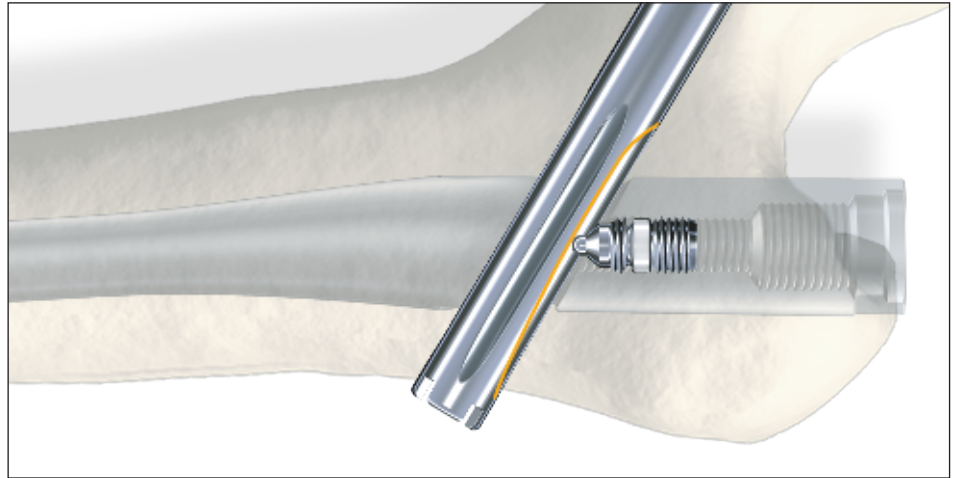


Fig. 62

Operative technique

**Alternative:
Set screw insertion with
Gamma3 closed tube clip**

Taking the Gamma3 closed tube clip and clipping it onto the Gamma3 targeting arm, it is possible to create a guided path for the set screwdriver. With this new feature, by pushing down the flexible set screwdriver into the nail axis, the set screw can be easily guided into the cannulation of the nail. It is possible to assemble the closed tube clip either prior to the nail insertion or prior to the set screw insertion as shown in Fig. 63a.

Step 1

Assemble the Gamma3 closed tube clip to the targeting arm by pressing the grip together and releasing it.

At this stage, you should assemble it slightly behind the groove of the targeting arm (Fig. 63a).

Step 2 and Step 3

Hold the targeting device and closed tube clip together, then push closed tube clip with your thumb in the direction shown by the arrow until it clicks onto the final position (Fig 63b and 63c).

Step 4

Insert the set screw according to the normal procedure (Fig. 63d).

Caution:

The Gamma3 closed tube clip is designed for the flexible set screwdriver (1320-0233) only and NOT for the straight screw driver (1320-0210) or (1320-0230).



Fig. 63a



Fig. 63b



Fig. 63c

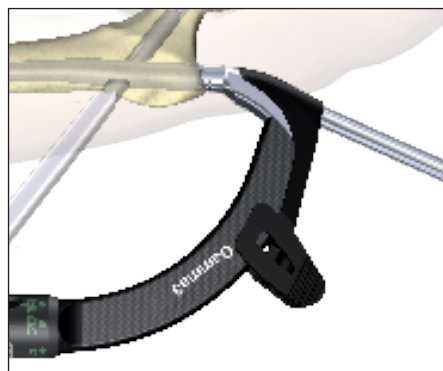

Fig. 63d

Operative technique

Distal screw locking

Disconnect the lag screwdriver by loosening the end thumbwheel, remove the lag screwdriver, lag screw guide sleeve and the K-wire. The nature of the fracture determines whether the distal locking screw is used.

It should be used:

- If the fracture is unstable
- If rotational stability is required
- When there is a wide disparity between the diameter of the nail and the femoral cavity

Gamma3 nails offer the possibility to be locked distally either dynamically or statically. The fracture pattern determines the method of distal locking.

Note:

These following points must be considered in order to perform a proper distal locking procedure:

- Ensure that the nail holding bolt is still fully tightened
- Avoid soft tissue pressure on the distal locking sleeve assembly—therefore the skin incision would be made (co-linear) in direction of the sleeve assembly
- Check that the distal locking sleeve assembly with the trocar removed is in contact with the lateral cortex of the femur and is locked securely with the speedlock sleeve knob. Confirm final locking screw placement with A/P and lateral fluoroscopic X-ray.
- Neutralize the power tool weight during drilling procedure and do not apply force to the targeting arm
- Start the power tool before having bone contact with the drill
- Use sharp and center tipped drills only

The carbon fiber targeting device offers the option of guided distal locking in a dynamic or static position of the nail. The green coded targeting sleeve of the target arm has to be adjusted in the required position. In the following description, dynamic locking will be described. Turn the targeting sleeve

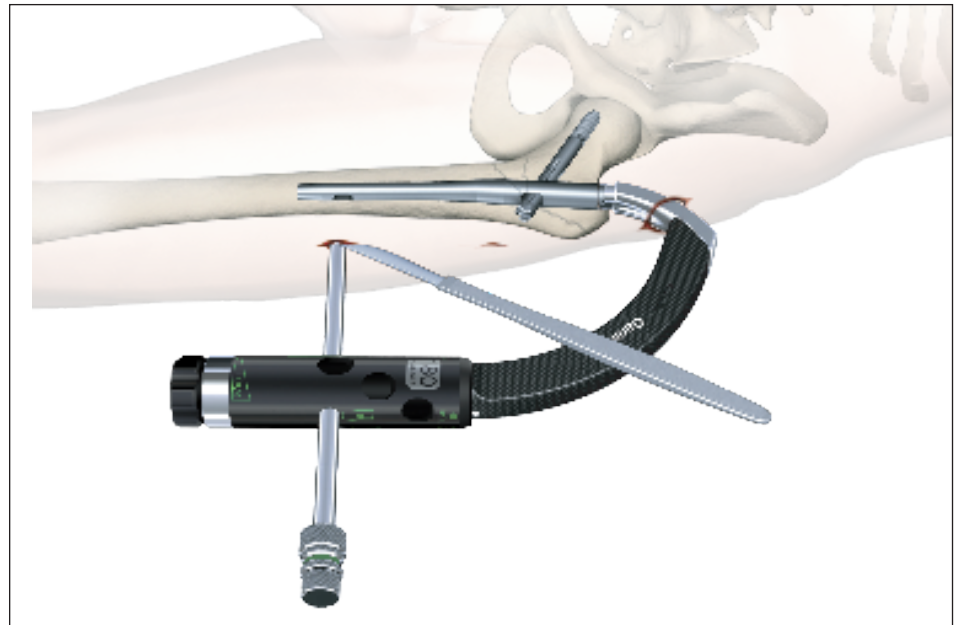


Fig. 64

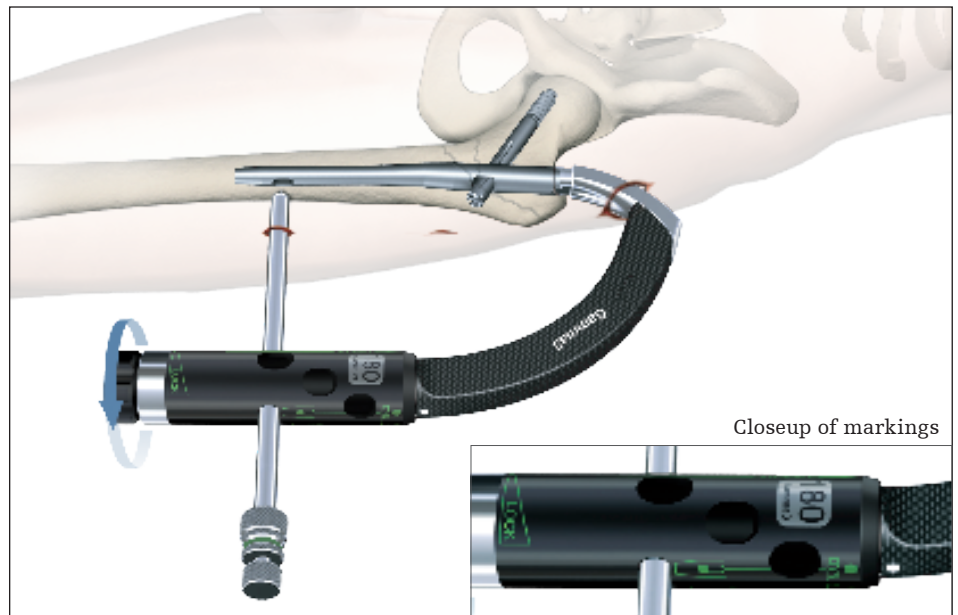


Fig. 65

until you reach the dynamic position with the point on the target sleeve is in line where the arrow on the target arm. Push the sleeve up in the cranial direction. Now assemble the tissue protection sleeve, Gamma3 drill sleeve and Gamma3 trocar and advance it through the hole of the target arm down to the skin.

A small incision is started at the tip of the trocar, and is extended down to the

lateral cortex (Fig. 64). The trocar will extend beyond the sleeve by approx. 3mm when the tissue protection sleeve has reached the lateral cortex (Fig. 65).

Before locking the sleeve, gently turn the speedlock sleeve knob clockwise, making sure that the tissue protection sleeve is in good contact with the bone (Fig. 65).

Operative technique

The Trocar is now removed and replaced by the calibrated green coded 4.2mm × 300mm drill. Drill through the first cortex and as the second cortex is reached read off the measurement on the drill scale. Add the thickness of the cortex, which is approximately 5mm, to this measurement to select the correct screw length (Fig. 66a).

Proceed to drill the second cortex. Alternatively, the drill can be drilled through the second cortex and monitored by X-ray or image intensifier. The screw length can then be read directly from the scale on the drill (Fig. 66b).

Proceed to drill the second cortex. It is also possible to measure the correct screw length using the screw gauge after drilling through the second cortex. The drill guide sleeve must be removed and the screw gauge may be advanced through the tissue protection sleeve. Put the small hook behind the medial cortex and read the required locking screw length from the scale.

Caution:
Make sure that the tissue protection sleeve/drill sleeve Assembly is seated on bone prior to selecting final screw length.

Insert the 5mm distal locking screw (Fig. 67) through the distal tissue protector by using the 3.5mm screwdriver until the mark on the screwdriver shaft approaches the protector; advance the screw head carefully until it is slightly in direct contact with the cortex.

Caution:
When the mark on the screwdriver shaft reaches the tissue protection sleeve, this indicates that the screw head is near the cortex (Fig. 67a). Take care not to overscrew. The screw head should come just into contact with the cortex and resistance should be felt.

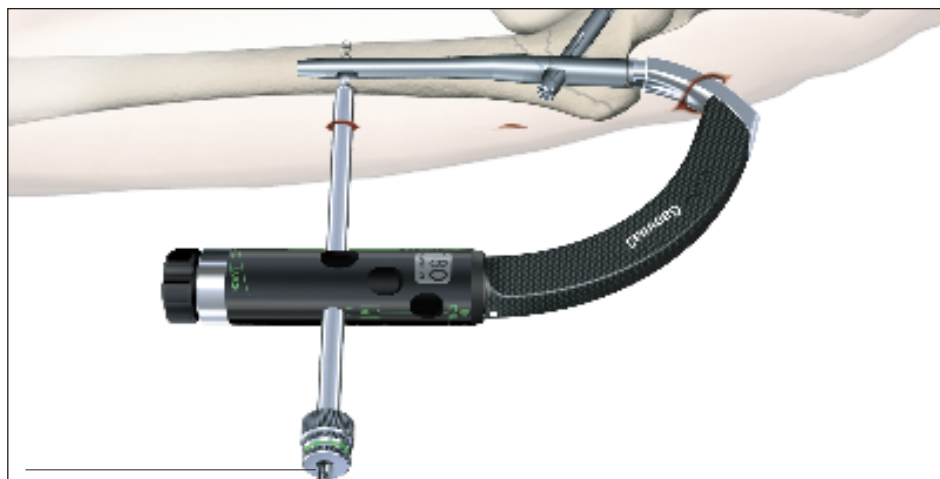


Fig. 66



+5mm


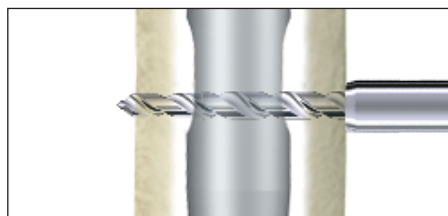


Fig. 66a



direct read out




Fig. 66b

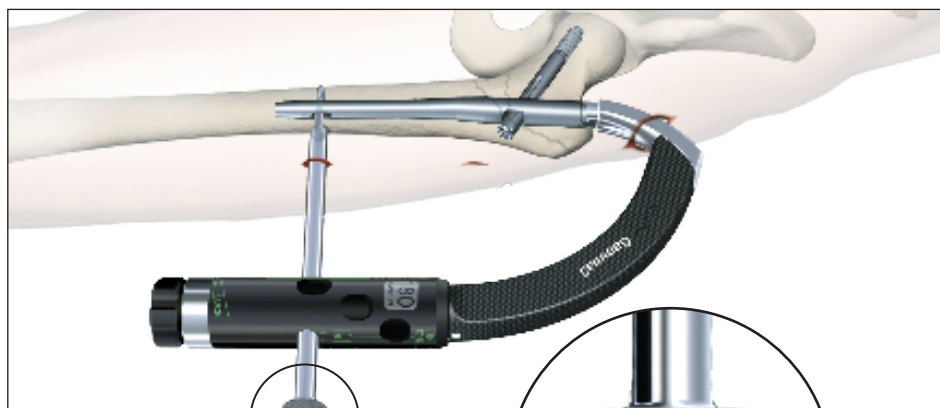


Fig. 67




Fig. 67a

Operative technique

End cap insertion

It is recommended to use an end cap to close the proximal part of the nail to prevent bone ingrowth.

Leave the screwdriver for the distalocking in place and remove the nail holding screw using the ball tip screwdriver, spreading screwdriver or screwdriver strike plate. Load the end cap (size 0) to one of the screwdrivers and pass the assembly through the top of the targeting device down into the nail.

Turn the handle clockwise until it stops mechanically. Remove the screwdriver, the distal screwdriver and the distal sleeves and remove the targeting device in cranial direction.

Alternatively the end cap could also be inserted free hand after removal of the target device.

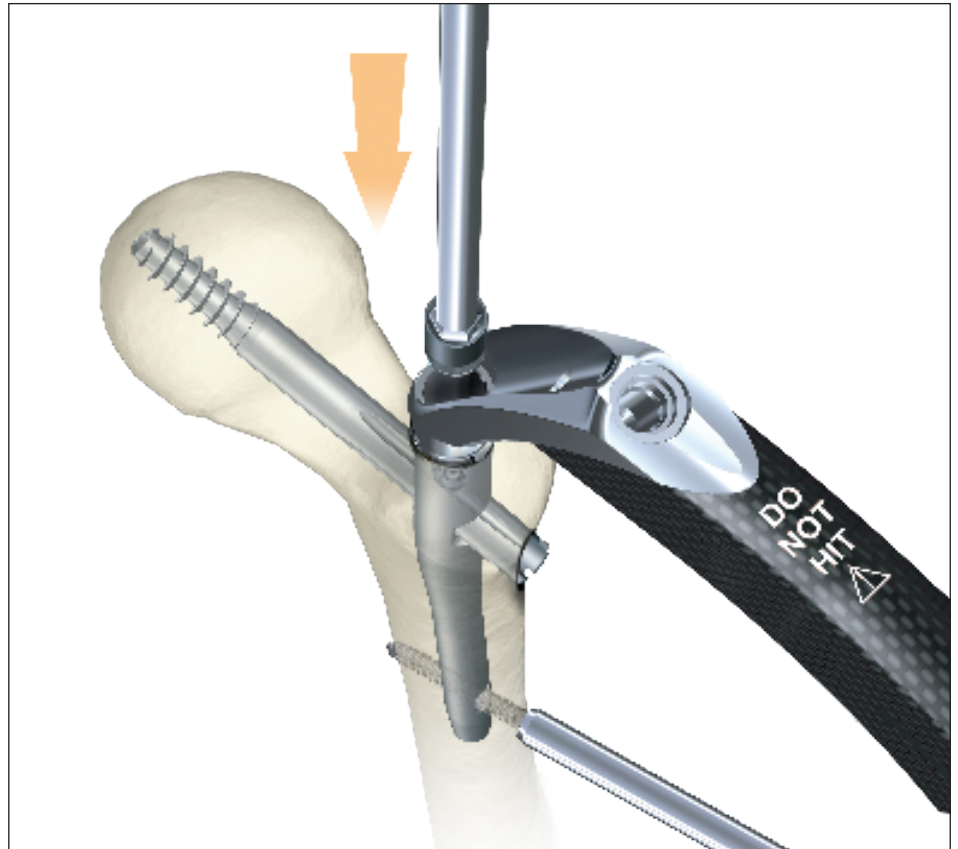


Fig. 68
End cap assembly

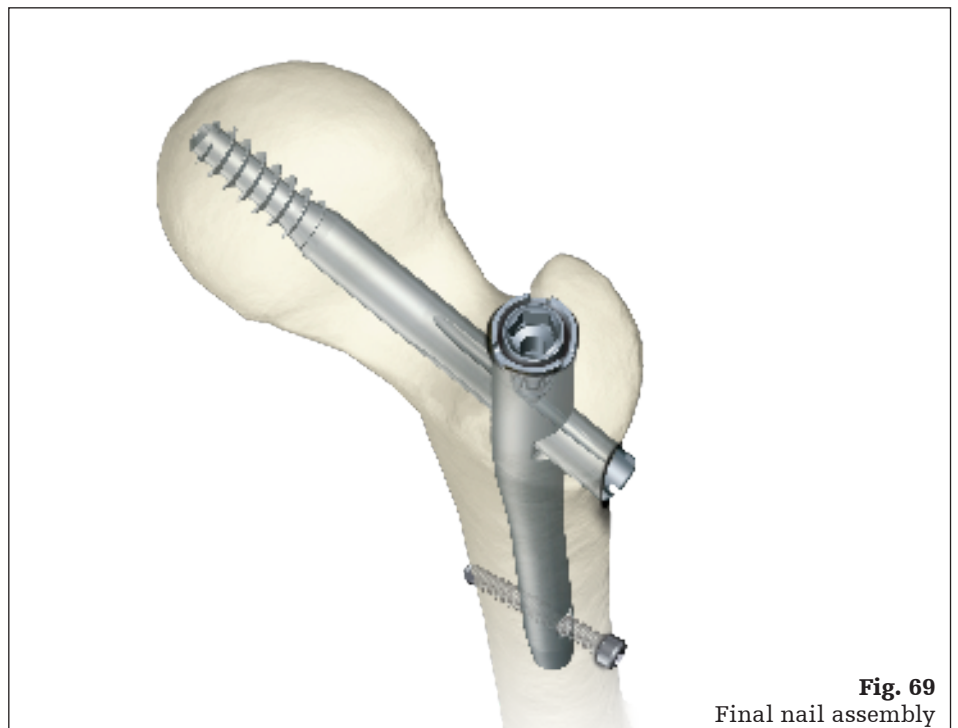


Fig. 69
Final nail assembly

Operative technique

Nail extension end caps

If the proximal end of the nail is completely in the trochanter and cortical bone support is required at the end of the nail, end caps in size +5mm and +10mm are available and can be assembled to the nail instead of the end cap size 0. The proximal part of the nail will be elongated by 5mm or 10mm.

The elongation end caps are assembled using the screwdriver strike plate with the self retaining ring, spreading screwdriver or ball tip screwdriver. This can only be done if the target device is already removed from the nail.

Post-operative care and rehabilitation

Active and passive mobilization of the lower limbs may be started immediately. The injured limb should be kept elevated.

For stable fractures with dynamic locking, full weight-bearing walking may be started immediately. For unstable fractures with static locking, immediate full weight-bearing walking is allowed in fractures with good bone contact.

For fractures with poor bone contact due to comminution, partial weight-bearing walking is allowed for the first 6 to 8 weeks. Full weight-bearing walking can be commenced when there is a bridging callus formed as evident on the follow up X-ray.




Fig. 70

Operative technique

Extraction of the Gamma3 implants

Where implant extraction is indicated, please proceed as follows:

Step I (Fig. 71)

Remove the distal screw using the 3.5mm screwdriver after making an incision through the old scar.

Step II (Fig. 72)

Make a small incision through the old scar below the greater trochanter to expose the outer end of the lag screw. Remove any bony ingrowth which may be obstructing the outer end or internal thread of the lag screw as necessary to enable the lag screwdriver to engage fully.

The K-wire is then introduced via the lag screw into the head of the femur. The lag screwdriver is passed over the K-wire, using the lag screw guide sleeve as a tissue protector, and engaged with the distal end of the lag screw.

Check that ingrowth does not obstruct secure engagement of the lag screwdriver, otherwise the lag screw or screwdriver may be damaged and extraction will be much more difficult. Tighten the thumbwheel clockwise.

Step III (Fig. 73)

An incision is made over the proximal end of the nail, the proximal end cap if used is removed using the ball tip screwdriver, spreading screwdriver or screwdriver strike plate, and the set screwdriver is engaged with the set screw. The screw is rotated counterclockwise until it is removed.

As the targeting device is not connected to the nail, we recommend using the straight set screwdriver for better guidance through the soft tissue to get access to the set screw.

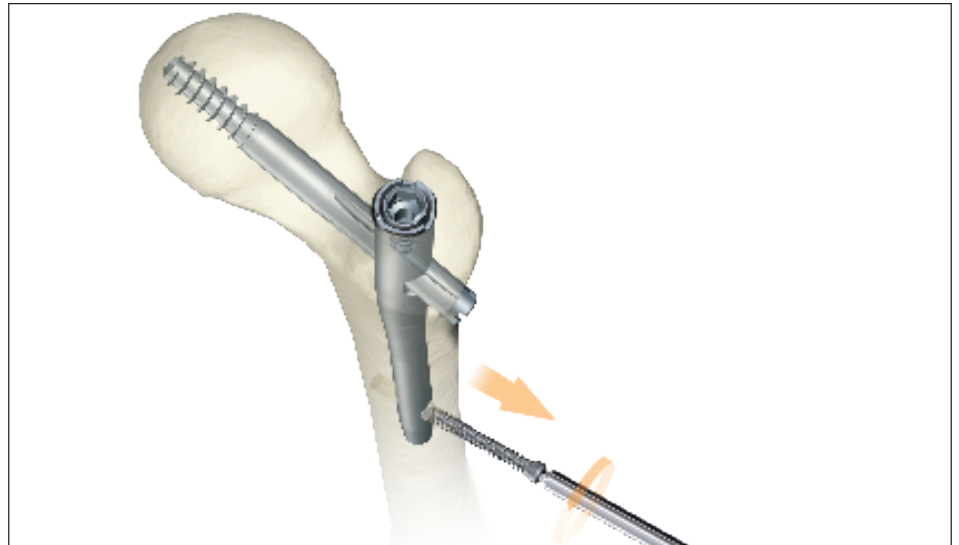


Fig. 71

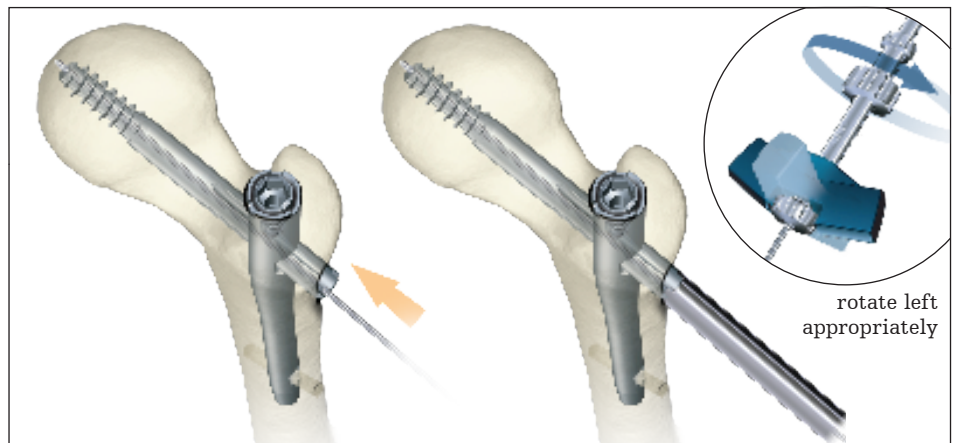


Fig. 72

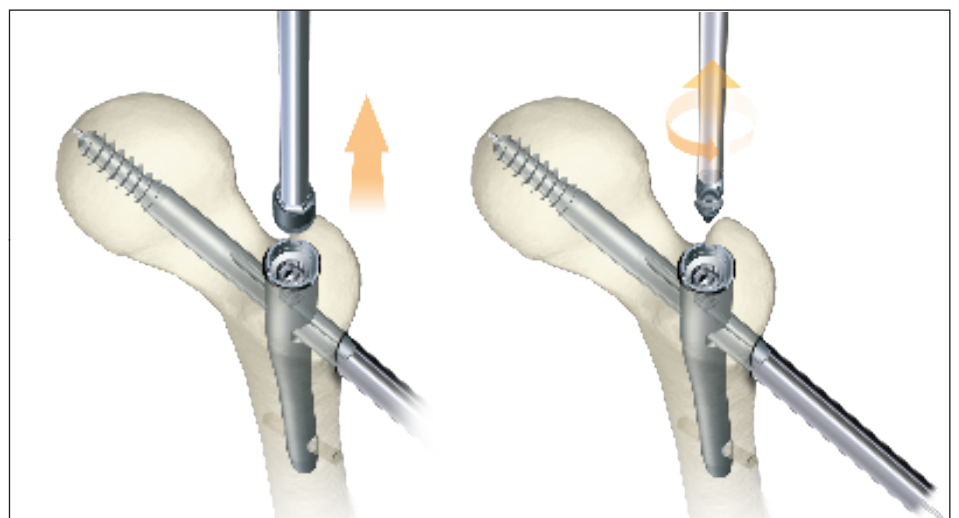


Fig. 73

Operative technique

Step IV (Fig. 74)

The nail extraction adapter is then threaded and tightened into the proximal end of the nail. The lag screw is extracted by anti-clockwise rotation and pulling of the lag screwdriver. The K-wire must then be removed.

Note:

It is useful to first turn the lag screw screwdriver clockwise slightly to loosen possibly bony ingrowth in the screw threads before turning it counter clockwise.

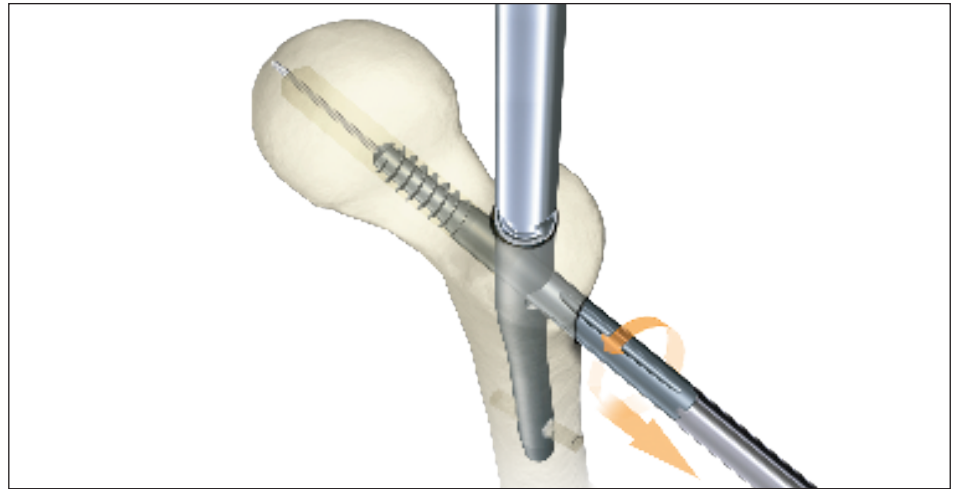


Fig. 74

Step V (Fig. 75a & b)

An appropriate sliding hammer assembly is attached to the nail extraction adapter and the nail is extracted.

Note:

It is useful to turn the lag screw screwdriver clockwise slightly first to loosen the possibly bony ingrowth into the screw threads before turning it counterclockwise.

As an alternative for implant extraction the Stryker implant extraction system can be used.

For details, please refer to the “implant extraction set” guide or ask Stryker representative for further assistance.

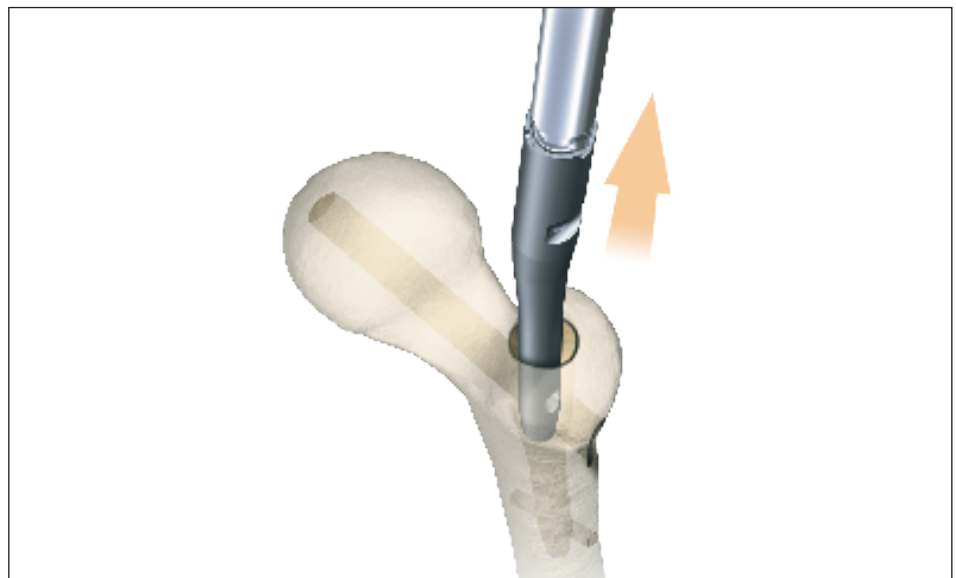
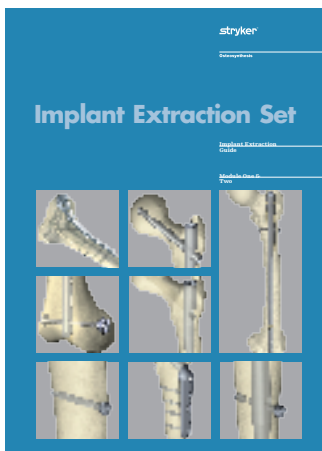


Fig. 75a



- Implant extraction set:
- Quick reference guide
 - Implant extraction guide

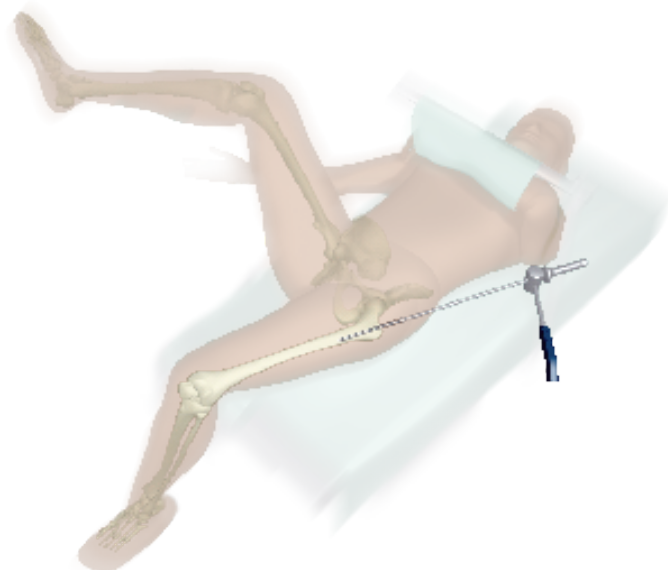


Fig. 75b

Operative technique

Dealing with special cases

In the case of a comminuted fracture, there is a tendency for the fracture to become displaced posterior, making it difficult to place the K-wire into the center of the neck and head. This can be solved by lifting the nail insertion targeting device (Fig. 76).

Alternatively, an assistant can lift up the greater trochanter manually or with a reduction spoon; or support it with a sandbag. This will maintain the neck and the femur in almost the same axis, facilitating passage of the K-wire through the center of the neck and head.

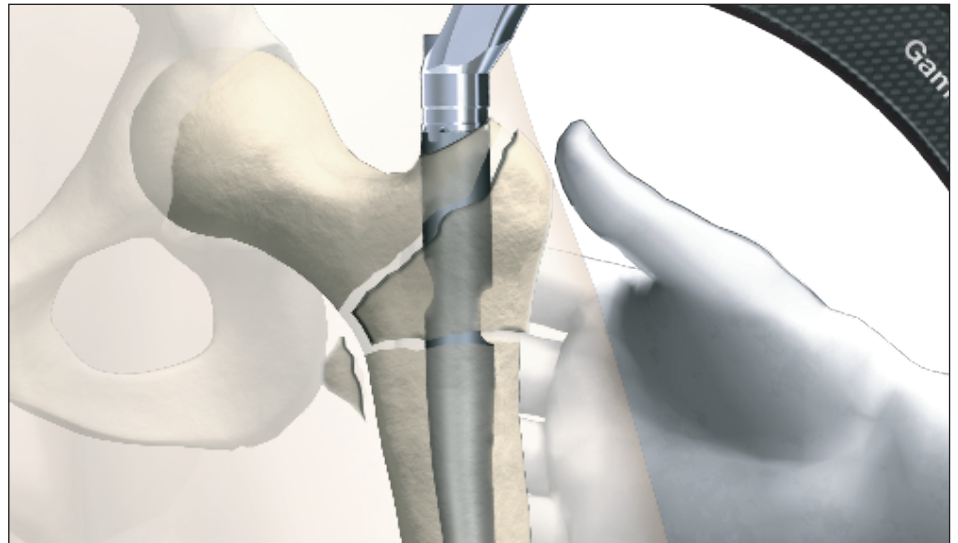


Fig. 76

In a case when the proximal fragment is split and making it difficult to place the K-wire into the center of the femoral neck and head, the reduction spatula can be utilized as an option. Enter with the reduction spatula from the same incision for the nail entry. Then slide the reduction spatula along the surface of the trochanter (Fig. 77a). Gently lift the lever to manipulate the region of the displaced fragment. It is important to continue holding the reduction spatula until the lag screw insertion is completed (Fig.77b).

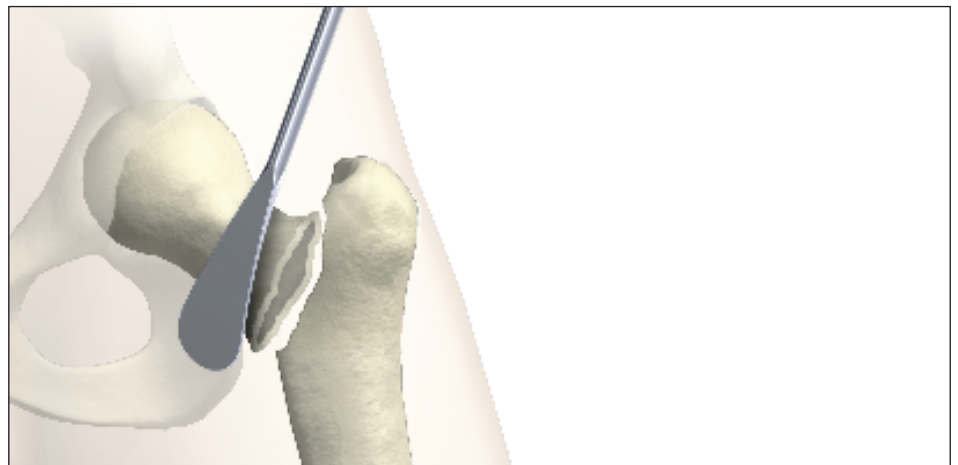

Fig. 77a

The position should then be checked in both the anterior-posterior and lateral views using the image intensifier.

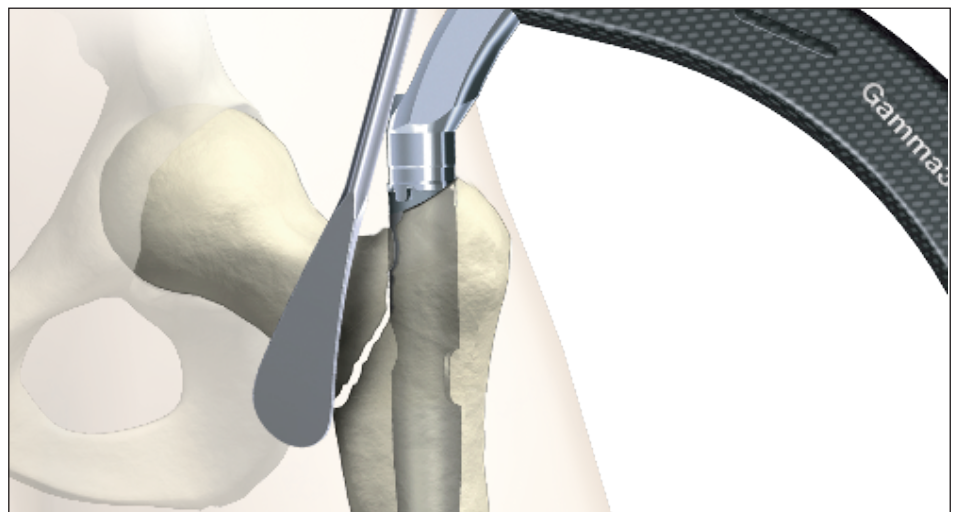


Fig. 77b

Implants

Packaging

All implants are packed sterile only.

The nail and lag screw implant have to be secured using the set screw in every surgical operation, without exception (see page 33).

The nail and the set screw are therefore supplied together in the same blister pack (Fig. 78).

The blister is packed in a white carton and wrapped to protect the contents during transportation and storage.

Only two package sizes are used for all the nails (Fig. 79).

The long nails are packed in a longer box and the short nails in a shorter box.

This facilitates identification in the storage area.

The package carries also the date of sealing and a sterility expiration date.

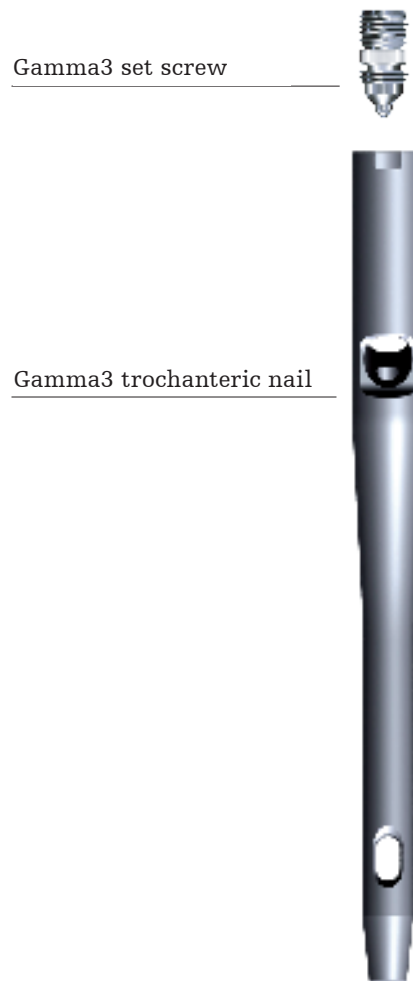


Fig. 78



Long nail, packaging example



Trochanteric nail, packaging example

Fig. 79

Trauma & Extremities

This document is intended solely for the use of healthcare professionals. A surgeon must always rely on his or her own professional clinical judgment when deciding whether to use a particular product when treating a particular patient. Stryker does not dispense medical advice and recommends that surgeons be trained in the use of any particular product before using it in surgery.

The information presented is intended to demonstrate a Stryker product. A surgeon must always refer to the package insert, product label and/or instructions for use, including the instructions for Cleaning and Sterilization (if applicable), before using any Stryker product. Products may not be available in all markets because product availability is subject to the regulatory and/or medical practices in individual markets. Please contact your Stryker representative if you have questions about the availability of Stryker products in your area.

Stryker Corporation or its divisions or other corporate affiliated entities own, use or have applied for the following trademarks or service marks: Bixcut, Gamma3, Stryker. All other trademarks are trademarks of their respective owners or holders.

The products listed above are CE marked.

Content ID: G3-ST-5, 10-2016

Copyright © 2016 Stryker



Manufacturer:

Stryker Trauma GmbH
Prof.-Küntscher-Str. 1-5
24232 Schönkirchen,
Germany

stryker.com